

ORIGINAL RESEARCH ARTICLE

Assessment of Physiological/Toxicological Effects of Camel Milk and Urine on Wistar Rats: A Study on Weight Gain, Haematological, Biochemical, and Histopathological Changes

Aremu Abdulfatai^{1*}, Oderinde Moyosore Hakeemat¹, Akorede Ganiu. Jimoh¹, Olatunji Omobolanle Aishat¹, Basiru Afisu² and Ahmed Olayiwola. Akeem³.

¹Department of Veterinary Pharmacology and Toxicology, Faculty of Veterinary Medicine, University of Ilorin, Kwara, Nigeria

²Department of Veterinary Physiology and Biochemistry, Faculty of Veterinary Medicine, University of Ilorin, Kwara, Nigeria

³Department of Veterinary Microbiology, Faculty of Veterinary Medicine, University of Ilorin, Kwara, Nigeria

ABSTRACT

This experiment was steered to observe the safety evaluation of camel milk and its urine on the physiological indices of experimental rats. Four groups of twenty Wistar rats each were formed: Group 1 (Control), 2 milk (2 ml/100 g), 3 (2 ml/100 g), and 4 (milk/urine combination). The result showed that all treatment groups experienced a significantly decreased body weight gain across day 1-14, which significantly increased between day 18-21, except for group 4, which decreased significantly. The PVC, RBC, and haemoglobin increased non-significantly in group 2 and decreased in groups 3 and 4. WBC decreased significantly in milk/urine combination compared to other treatment groups. Neutrophils, Lymphocytes, and Monocytes did not show significant alteration across all the treatment groups. ALT decreased non-significantly ($p > 0.05$) in all the treatment groups, while AST showed non-significant increased values in groups 2 and 3 except in group 4, which decreased significantly. Urea and creatinine decreased significantly ($p < 0.05$) in all the treatment groups. Cl of group 3 decreased significantly ($p < 0.05$), while it increased significantly ($p < 0.05$) in group 4. Na^+ showed significantly increased values across all the treatment groups while Bicarbonate decreased significantly in all the treatments. Ca^{2+} increased non-significantly. Histopathology results showed that group 4 has arrays of lesions compared to those treated separately. There was no observable lesion in these organs in group 2. It can be concluded that camel milk and its urine might have some beneficial effects when dosed separately, but they might predispose to harmful effects when combined.

ARTICLE HISTORY

Received April 06, 2024.

Accepted June 22, 2024.

Published July 04, 2024.

KEYWORDS

Camel milk; camel urine, weight gain; Haemobiochemical parameters; Wistar rats.

© The authors. This is an Open Access article distributed under the terms of the Creative Commons Attribution 4.0 License (<https://creativecommons.org/licenses/by-nc/4.0/>)

INTRODUCTION

The World Health Organization estimated that the majority of the world's population primarily uses medicines made from animals and plants (WHO, 2019), although reports have shown that animal products are more frequently used compared to plant resources (Glencross *et al.* 2020). In China, medicinal applications for around 1,500 animal species have been found (Deyrup *et al.*, 2021). Around 250 animal species are supposedly utilised medicinally in North-East Brazil, whereas at least 109 animals have been employed for traditional medical purposes in India (Alves and Rosa 2005). A significant number of animals have reportedly been utilised in Ghana, South Africa, and Nigeria to treat various illnesses (Adeola, 1992; Mensah *et al.*, 2019).

For millennia, camel milk and urine have been an essential part of traditional medicine and diets in numerous civilizations worldwide (Al-Moosawi *et al.*, 2023). Modern scientific studies have confirmed the historical applications of camel milk and urine for medical purposes (Bakhsh *et al.*, 2023).

Within traditional medicine, drinking camel urine either alone or when combined with milk is a well-known episode (Mok *et al.*, 2021). This practice has been widely reported in Arabian nations, such as people of Bedouin communities who have a strong Islamic connection (Ali *et al.*, 2019; Al-Yousef *et al.*, 2012); among these tribes, the most highly prized urine is that of virgin female camels (Abdelzaher *et al.*, 2020). But camel urine has historically

Correspondence: Aremu Abdulfatai. Department of Veterinary Pharmacology and Toxicology, Faculty of Veterinary Medicine, University of Ilorin, PMB 1515, Ilorin, Nigeria. ✉ aremu.a@unilorin.edu.ng. Phone Number: +234 806 349 1036.

How to cite: Aremu, A., Oderinde, H. M., Akorede, G. J., Olatunji, A. O., Basiru, A., & Ahmed, A. O. (2024). Assessment of Physiological Effects/Toxicity of Camel Milk and Urine on Wistar Rats: A Study on Weight Gain, Haematological, Biochemical, and Histopathological Changes. *UMYU Scientifica*, 3(3), 31 – 37. <https://doi.org/10.56919/usci.2433.004>

been used more than other animal urine because it is much more alkaline (high potassium and magnesium levels, albuminous protein, and low percentages of uric acid, salt, and creatine) than other animal urine (Alkhamees and Alsanad 2017).

Camel milk is vividly different from that of stomach animals (ruminant) milk in that it contains protective proteins such as lactoferrin, lactoperoxidase, immunoglobulin, and lysozyme, low cholesterol, low sugar, high minerals, and vitamin C (Yadav *et al.*, 2015). Camel milk contains lactoferrin, which is ten times more abundant than lactoferrin in cow milk and has antimicrobial and antiviral properties like lysozyme and immunoglobulins (Swelum *et al.*, 2021). According to reports, camel milk has low quantities of β -lactoglobulin and β -casein, making lactose intolerant experience hypersensitivity reactions (Konuspayeva *et al.*, 2009).

Worries about possible health dangers of camel milk and urine and individuals sensitive to dairy products have been reported with significant adverse effects such as allergic reactions following its consumption (El-Aziz *et al.*, 2022).

This research was designed to objectively assess the physiological/safety evaluation of camel milk and its urine using body weight, haematological, serum biochemistry, and histopathological changes as physiological/toxicological indices in male Wistar rats.

Table 1: **Twenty Male Wistar rats divided into 4 groups (n= 5), each consisting of five rats per group**

Grp 1	Control rats received normal saline orally for 21 days.
Grp 2	Received Camel's milk at the dose of 2 ml/ 100 g by oral gavage for 21 days
Grp 3	Received Camel's urine at the dose of 2 ml/100 g by oral gavage for 21 days
Grp 4	Received the combination of camel milk and its urine (1:1) at 1 ml /100 g by oral gavage for 21 days

Key: Grp = Group

Determination of weight gain

On days 1, 4, 7, 10, 13, 15, 18, and 21, the weights of the experimental mice were recorded using an automatic microelectronic scale (SDT[®], London). A circular flexible bowl was put on the scale to measure the rat's weight, tarred to zero and subsequently measured.

Determination of haematological parameters

The entire blood in the EDTA bottles was utilized to assess various haematological parameters. PCV, HB Conc, and RBC were evaluated using Cole's method (Cole, 1986). Other parameters, including Total WBC, monocytes, lymphocytes, and neutrophils, were also assessed.

Determination of serum biochemical and electrolyte parameters

Creatinine, Blood Urea Nitrogen, Transferase Alanine Phosphatase, and Aspartate Transferase were analyzed. Serum electrolyte analysed includes sodium, potassium, calcium, chloride, and Bicarbonate following standard methods.

METHODOLOGY

Acquisition of camel milk and urine

Fresh milk and urine (Camel) were obtained from a reliable source. During the study, milk and urine were kept in a refrigerator at 4°C.

Ethical Consideration

Ethical consent was obtained from the Board in charge of animal use and care at the University of Ilorin, Nigeria, with ethical approval number **UERC/FVM/2021/020**

Experimental Animals and Design

Twenty male Wistar rats weighing 120-170 g were used for this experiment. Rats were acquired from a reliable source. They were housed in a hygienic cage, handled with proper care, and fed with standardized pelletized feed (Chikun Feeds [®], Chikun Nig. Ltd), and the supply of uncontaminated water was given *ad libitum*. Two weeks before the trial started, the rats were given time to get used to the lab setting. All experimental rats were confirmed to be apparently healthy, which was identified by their colour tail marks. Experimental Albino rats were allotted to different groups, as shown in Table 1.

Animal sacrifice and tissues Sample Collection

The rats in all the groups were sacrificed humanely using ether as light anaesthesia. A small quantity of ether was placed on cotton wool to achieve this. The rat was placed in a small air-tight plastic container, and the ether-soaked cotton wool was placed on the nostril of the rat and subsequently covered. The anaesthetized rats were humanly killed after a few minutes. The heart, kidney, and liver were harvested for histopathology.

Histological procedures

The organs were appropriately treated with 10% formaldehyde (fixation) following the rats' deaths to maintain their molecular makeup and structural integrity. The organs were dehydrated by gradually immersing these organs in a graded blend of ethanol and water. A solvent that could be mixed with the embedding media was used in place of ethanol. After injected xylene into the tissues, it cleared, or became transparent. The xylene-infused tissue was embedded in an oven with molten paraffin at 58 to 60 degrees Celsius. The solvent was able to evaporate due to the heat, and paraffin filled the spaces inside the tissues. After removing the tissue from the

oven, it solidified with its impregnating paraffin. Subsequently, the 5-micrometer pieces were submerged in water, moved to a glass slide, and stained with eosin and hemophthalein stains. After the slides floated on the water, they were examined using a light microscope at a magnification of x 40 (Aremu *et al.*, 2022).

Data analysis

Every created set of data was shown as mean ±Standard Deviation. Using the Dunnet Post-hoc multiple comparison test and the Graph Pad Prism statistical programme, the changes within the groups were examined using one-way ANOVA (www.Graphpad.com).

RESULT

Effect of camel milk and its urine on body weight

The weights of the rats reduced non-significantly (p< 0.05) from day 1 to 14. The weight of the rats started increasing from day 18 to 21 except for group 4 (Camel milk and its urine combined), which showed a steady decrease in weight gain across all the treatment days. There is a significant change in the rats' weight compared to the untreated control.

Table 2: Changes in weight (g) gain of Wistar rats administered camel milk and its urine.

Days	Group 1	Group 2	Group 3	Group 4
DAY 1	155.7±14.86	162.6±10.27	176.625±15.62	196.1±8.533
DAY 4	150.0±14.71	161.7±8.82	170.5±12.28	181.2±11.80
DAY 7	148.02±17.79	157.65± 10.17	163.4±9.801	178.2±10.90
DAY 10	146.5±22.20	154.8±13.45	161.2±14.50	177.5±9.370
DAY 14	132.0±23.60	146.8±16.63	159.4±11.92	169.7±20.25
DAY 18	134.2±25.04	150.0±15.20	160.0±11.53	168.3±19.41
DAY 21	138.1±27.07	153.2±14.93	164.3±10.23	166.5±17.53

Values are expressed as mean ±SD

Haematology following treatment with camel milk and its urine in Wistar rats

The haematology following various treatments with camel milk and its urine showed that PVC, RBC, and haemoglobin (Hb) increased non-significantly in group 2 (camel milk) while it decreased significantly (P<0.05) in group 3 (camel urine) and 4 (milk and urine combination) when compared to group 1 (untreated control). MCV and MCHC relative reduction in camel milk and its urine groups while MCH relatively increased compared to the control group

Compared to the other treatment sets and untreated control, WBC considerably decreased in milk/urine combination (grp 4). Compared to untreated control, all therapy groups did not significantly change in the differential WBC count, including neutrophils, lymphocytes, and monocytes. In contrast to the other treatment groups and the untreated control, the platelet counts of group 4 (milk and urine combination) (1.84±0.44 X10⁵/µl) decreased significantly (p<0.05), as stated in Table 3.

Table 3: Haematology of Wistar rats administered camel milk and its urine.

Parameters	Grp 1	Grp 2	Grp 3	Grp 4
PCV (%)	38.50±2.08	39.25±2.50	35.80±3.56 ^a	35.25±3.59 ^a
RBC×10 ⁶ /µl	6.61±0.33	6.87±0.30	6.21±0.68	6.25±1.14
HB (g/dl)	12.22±1.05	12.91±0.95	11.30±1.34	10.71±1.12
MCV (fl)	58.28±5.08	57.18±4.26	57.42±5.29	58.23±4.93
MCH (pg)	18.48±1.76	18.80±1.64	17.80±4.26	17.80±1.79
MCHC (g/dl)	31.63±1.66	30.60±0.41	30.90±1.15	31.00±1.71
WBC×10 ³ /µl	7.35±2.08	7.90±1.64	7.10±1.04	6.39±1.04 ^a
Lymph (%)	65.25±3.86	63±3.16	64.20±5.26	66.50±1.73
Neutro (%)	31.50±3.11	35.50±3.78	33.20±4.82	30.00±1.63
Mono (%)	2.00±0.82	1.50±0.71	1.60±0.89	2.00±0.82
Platelet ×10 ⁵ /d/µl	1.97±0.82	2.03±0.81	2.08±1.13	1.84±0.44^a

Data represented as Mean ±SD; No. of Wistar rats in each group=5; Significant ^aP≤0.05; Grp: Group

Serum chemistry following treatment with camel milk and its urine in Wistar rats

Serum chemistry following treatment with camel milk and its urine showed that ALT decreased non-significantly (p>0.05) in all the treatment groups, while AST showed non-significant increased values in groups 2 (camel milk)

and 3 (camel urine) except group 4 (milk and urine) that decrease significantly when compared to the control. Urea and creatinine decreased significantly (p<0.05) when compared to the control group in each of the therapy groups (Table 4).

Serum electrolytes following treatment with camel milk and its urine in Wistar rats

When compared to other treatment groups and the untreated control, the serum chloride ion of group 3 (camel urine) decreased significantly ($p < 0.05$), but it increased significantly ($p < 0.05$) in group 4 (milk/urine combination). Sodium ion (Na^+) showed a significant

($p < 0.05$) increase in values across all treatment groups when compared to the untreated control. Bicarbonate (HCO_3^-) decreased significantly in all the treatments compared to the control. Potassium (K^+) did not show any alteration in all treatments compared to the control, but calcium increased non-significantly in all treatments compared to the control (Table 4).

Table 4: Serum and Biochemical values of Wistar rats administered camel milk and its urine.

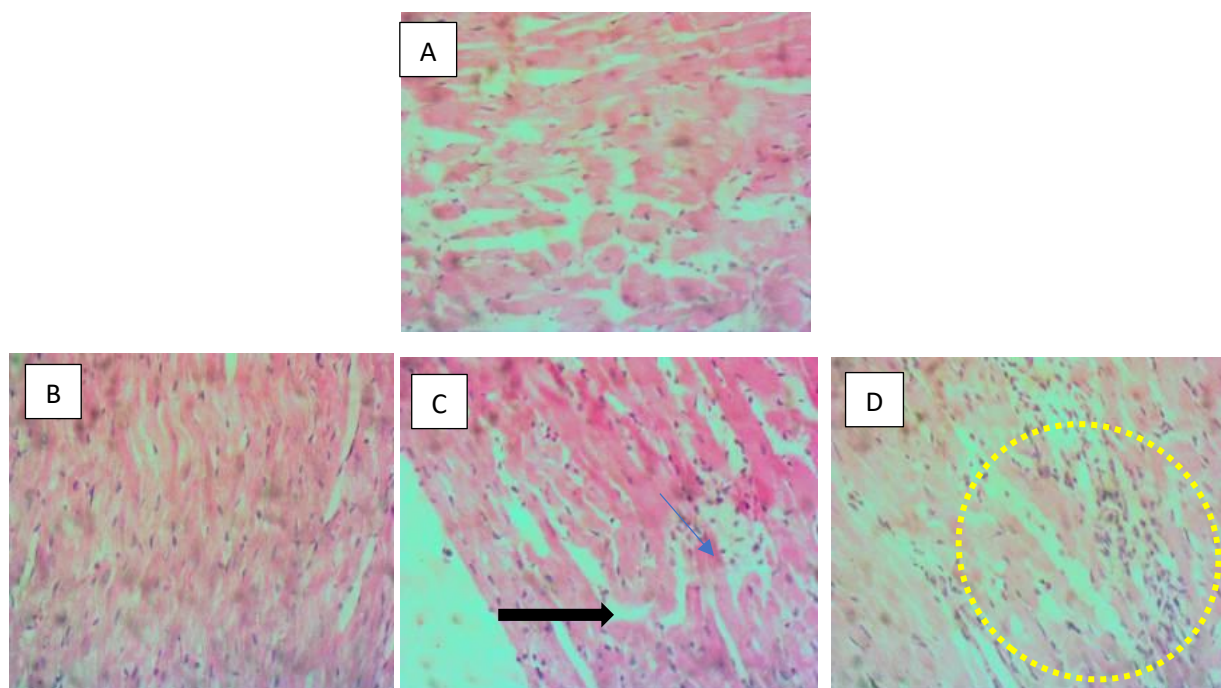
PARAMETER	Grp 1	Grp 2	Grp 3	Grp 4
ALT (mmol/l)	15.78±7.14	9.00±1.89 ^a	13.58±2.70 ^a	12.10±2.68 ^a
AST (mmol/l)	31.03±9.08	30.93±14.75	30.66±25.25	26.63±11.32 ^a
ALP (mmol/l)	23.63±11.41	17.15±6.99	15.20±7.55	17.23±3.62
Urea (mmol/l)	4.80±2.24	4.77±1.11	4.44±3.87	4.13±7.48
Creatinine. (µmol/l)	113.10±49.92	78.78±7.77	104.54±5.40	87.65±12.59
Potassium ion (µmol/l)	3.35±0.47	3.03± 0.41	3.88±1.06	3.75±0.38
Chloride ion (µmol/l)	89.63±11.07	89.50±3.43	82.86±10.96 ^a	96.28±14.26 ^a
Sodium ion (µmol/l)	131.90±2.95	137.30±7.62	133.20±7.91	133.30±8.63^b
Bicarbonate ion (µmol/l)	17.25±1.99	15.68±2.22	16.10±1.33^a	17.03±4.58^a
Calcium ion (µmol/l)	0.70±0.27	0.76±0.31	0.77±0.35	0.69±0.35

Data rep. as Mean ±SD: n=5

Significant ^a $p \leq 0.05$

Grp: Group

Histopathology result of the heart of Wistar rats administered camel milk and its urine.



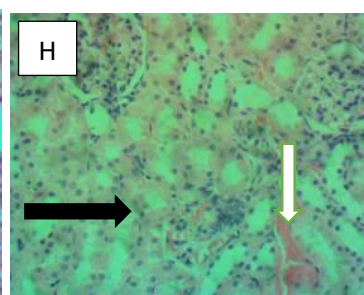
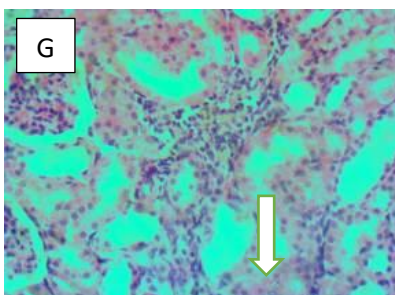
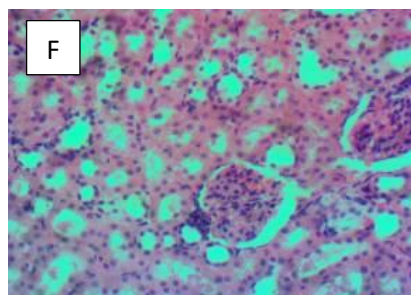
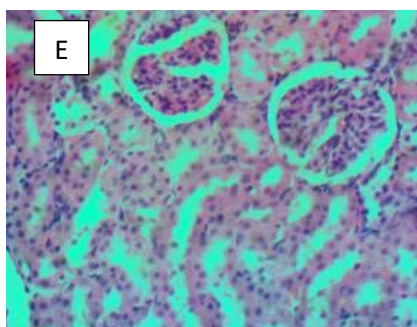
A: Section of the heart of rats in the untreated control (H&E) showing no observable visible lesion

B: Section of the heart of rats treated with camel milk showing no observable visible lesion (H&E)

C: Section of the heart treated with camel urine with mild necrotizing myocarditis (arrows) (H&E)

D: The section of the heart of rats treated with camel milk and its urine showing severe necrotizing myocarditis (dotted circle) (H&E).

Histopathology result of the kidney of Wistar rats administered camel milk and its urine.



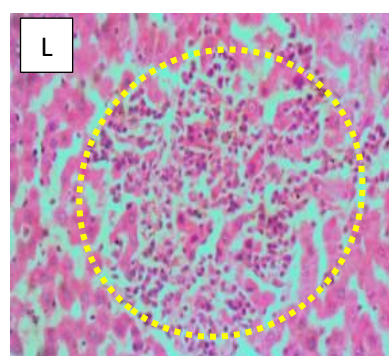
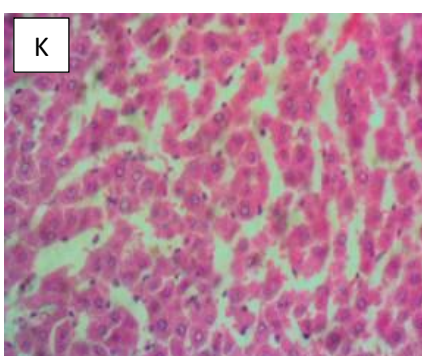
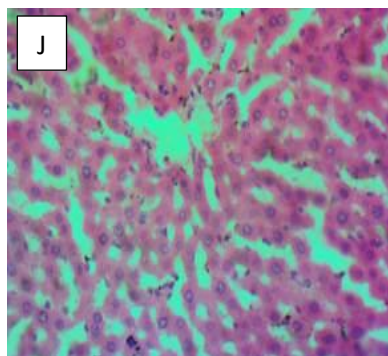
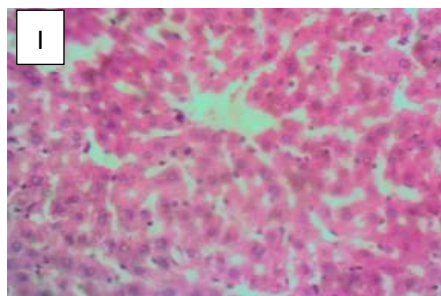
E) Section of the kidney of rats; the control showing no observable visible lesion (H&E).

F) Section of the kidney treated with camel milk without observable lesion (H&E)

G) Section of the kidney treated with camel urine showing patchy tubular epithelial coagulation necrosis (arrow) (H&E)

H) Section of the kidney treated with combination of camel milk and its urine with patchy tubular epithelial coagulation necrosis and peri-tubular inflammatory cells (Arrows) (H&E).

Histopathology result of the liver administered camel milk and its urine.



I) Section of the liver of rats; the control and untreated (H&E) showing no observable visible lesion

J) Liver section treated with camel milk showing moderate centrilobular cord atrophy (H&E).

K) Liver section treated with camel urine with moderate hepatocellular atrophy (H&E)

L) Liver section treated with a combination of camel milk and its urine showing severe necrotizing hepatitis and hepatocellular vacuolar degeneration (Dotted circle) (H&E).

DISCUSSION

Reports have shown that significantly decreased body weight may be a pointer to various responses, such as treatment-induced toxicity (Aremu *et al.*, 2023). The results from this study showed that the weight of the rats reduced from day 1-14 across all the treatment groups indicating a negative effect of the treatment on the growths of the rats. This result conforms with the report of a previous study by Al-Anazi *et al.* (2022), who recorded a significant weight reduction in rats fed with fermented camels' milk and high-cholesterol diets. The initial weight loss in all groups might be due to the sudden introduction of camel milk and urine into the rat's diets which might have disrupted their gut microbiome and digestion (Al-Beltagi *et al.*, 2023). Another possible reason is that camel milk and urine are known to possess anti-inflammatory and anti-oxidative properties, which could have initially suppressed the growth of certain gut bacteria, leading to a temporary reduction in nutrient absorption and weight loss. The weight started increasing from day 18 to 21 across the treated groups. This might be attributed to the adaptation pathway to the nutritional profile of camel milk and urine that could have promoted the growth of beneficial gut bacteria over time, leading to improved nutrient absorption and weight gain. This assertion agrees with Ibrahim *et al.* (2018), who assessed the hepatocurative potentials of camel milk and urine on CCl₄-induced hepatotoxicity in albino rats showing altered weight gain across the duration of the experiment. The steady weight loss observed in group 4 (milk/urine combination) could have resulted in unexpected negative effects on nutrient absorption, leading to consistent weight loss.

According to reports, haematological indices are a key indicator of toxicity with a high degree of predictive ability for systemic toxicity when exposed to chemicals, medications, whole plants, or animal products (Aremu *et al.*, 2023). This study suggests that camel milk and its urine have a deleterious effect on the haematological parameters, resulting in various degrees of anaemia as observed with decreased PCV, RBC, and haemoglobin values, especially in camel milk/urine combination. This outcome agrees with Manav *et al.* (2019), who reported significantly decreased PCV, RBC, and haemoglobin in rats treated with camel milk/urine combination. This study's result specifically showed a significantly decreased platelet count in group 4 (milk/urine combination), which can lead to blood clot abnormalities when taken for a long time.

The treated groups showed lower serum AST, ALT, and ALP activities, indicating that camel milk and/or urine have hepato-protective activities. This observation agrees with Ibrahim *et al.* (2018), who stated that camel milk and its urine possess significant hepato-protective potentials in tetrachloride-induced hepatotoxicity.

Serum electrolytes like urea and creatinine are usually used as major biomarkers in kidney function (Aremu *et al.*, 2023). This present study showed no significant

alterations in the kidney's level of creatinine, urea, Na, K⁺, Cl⁻, and HCO₃⁻ in all the treatment groups. The creatinine and urea levels showed significantly decreased values, indicating that camel milk and urine are not nephron-toxic.

The histopathology results showed that the combination of camel milk and its urine (group 4) showed various degrees of lesion in the heart, kidneys, and liver compared to the other groups dosed separately. There was no observable lesion in these organs in group 2 (camel milk) compared to the untreated group.

The inference deduced from this work showed that camel milk/urine combination can pose a deleterious effect on these organs, leading to a marked toxicity when used for a long time.

CONCLUSION

Drawing on the study's findings, it can be said that camel milk and its urine have different effects on the body weight and health of rats. Camel milk and its urine might have some beneficial effects when dosed separately, but they might predispose to harmful effects when combined.

LIMITATIONS AND FURTHER RESEARCH

The scope of this research did not cover molecular and mechanistic approaches of assessing camel milk and urine toxicity in the biological system.

Further studies could focus on evaluating the long-term effects of camel milk and urine exposure, considering different dosages and durations of treatment to assess both short-term and chronic impacts on animal health outcomes using molecular and mechanistic approaches.

ACKNOWLEDGMENT

We appreciate the technologist from the Department of Veterinary Pathology for the slides sectioning of all histopathology blocks.

CONFLICT OF INTEREST

No conflicting interest

REFERENCES

- Abdelzaher, H. M., Alsuhaymi, M., Alshammari, F. M., Alshammari, S. A., and Alshammari, Z. M. (2020). Evaluation of the effectiveness of virgin camel's urine as antifungal agents. *Journal of Bacteriology and Mycology*: 8(1), 124-128. [\[Crossref\]](#)
- Adeola, M. O. (1992). Importance of wild animals and their parts in the culture, religious festivals and traditional medicine in Nigeria. *Environmental Conservation*, 19(2), 125-134. [\[Crossref\]](#)
- Al-Anazi, M. S., El-Zahar, K. M., & Rabie, N. A. H. (2022). Nutritional and Therapeutic Properties of Fermented Camel Milk Fortified with Red Chenopodium quinoa Flour on

- Hypercholesterolemia Rats. *Molecules*, 27(22), 7695. [\[Crossref\]](#)
- Al-Beltagi, M., Saeed, N. K., Bediwy, A. S., Elbeltagi, R., & Alhawamdeh, R. (2023). Role of gastrointestinal health in managing children with autism spectrum disorder. *World Journal of Clinical Pediatrics*, 12(4), 171. [\[Crossref\]](#)
- Ali, A., Baby, B., & Vijayan, R. (2019). From desert to medicine: A review of camel genomics and therapeutic products. *Frontiers in Genetics*, 10, 17. [\[Crossref\]](#)
- Alkhamees, O. A., and Alsanad, S. M. (2017). A review of the therapeutic characteristics of camel urine. *African Journal of Traditional, Complementary and Alternative Medicines*, 14(2), 120-126. [\[Crossref\]](#)
- AL-Moosawi, Z. H., Almahdawi, M. K., & Al-Charak, A. G. (2023). Camel milk as an integrated food and its physical and chemical properties with therapeutic characteristics. *International Journal of Veterinary Science and Animal Husbandry*, 8, 90-96. [\[Crossref\]](#)
- Alves, R., and Rosa, I. (2005). Why study the use of animal products in traditional medicines? *Journal of Ethnobiology and Ethnomedicine*, 1, 5. [\[Crossref\]](#)
- Al-Yousef, N., Gaafar, A., & Al-Otaibi, B. (2012). Camel urine components display anti-cancer properties in vitro. *Journal of Ethnopharmacology*, 143(3), 819-825. [\[Crossref\]](#)
- Aremu A, Oridupa O. A, Akorede G.J, Basiru A, Suleiman K.Y, Ahmed O. A. and Raufu I. A. (2022): Fractions of *Lawsonia inermis* Linn leaves improved the histomorphological appearance of major organs involved in diabetic complications. *Journal of Sustainable Veterinary and Allied Science*. 2:(1-6): 136-139. [\[Crossref\]](#)
- Aremu, A., Oridupa, A. O., Basiru, A., Akorede, G. J., & Ahmed, O. A. (2023). Safety evaluation of bioactive sub-fraction of *Lawsonia inermis* Linn. leaves in male Wistar rats. *Sabel Journal of Veterinary Sciences*, 20(1), 22-27.
- Bakhsh, R. S., Turkistani, S. A., Felemban, S. G., & Al-Hejin, A. M. (2023). The Effect of Camel Products Against Microbial Infections: A Systematic Review Literature. *Advances in Environmental Biology*, 17(5), 1-9.
- Deyrup, S. T., Stagnitti, N. C., Perpetua, M. J., & Wong-Deyrup, S. W. (2021). Drug discovery insights from medicinal beetles in traditional Chinese medicine. *Biomolecules & therapeutics*, 29(2), 105. [\[Crossref\]](#)
- El-Aziz, A., Kassem, J. M., Aasem, F. M., & Abbas, H. M. (2022). Physicochemical properties and health benefits of camel milk and its applications in dairy products: A review. *Egyptian Journal of Chemistry*, 65(5), 101-118.
- Glencross, B. D., Baily, J., Berntssen, M. H., Hardy, R., MacKenzie, S., & Tocher, D. R. (2020). Risk assessment of the use of alternative animal and plant raw material resources in aquaculture feeds. *Reviews in Aquaculture*, 12(2), 703-758. [\[Crossref\]](#)
- Ibrahim, M., Rehman, K., Razzaq, A., Hussain, I., Farooq, T., Hussain, A., & Akash, M. S. H. (2018). Investigations of phytochemical constituents and their pharmacological properties isolated from the genus *Urtica*: critical review and analysis. *Critical Reviews™ in Eukaryotic Gene Expression*, 28(1). [\[Crossref\]](#)
- Konuspayeva, G., Faye, B., & Loiseau, G. (2009). Fatty acid and cholesterol composition of Camel's (*Camelus bactrianus*, *Camelus dromedarius* and hybrids) milk in Kazakhstan. *Dairy Science and Technology*, 88(3), 327-340. [\[Crossref\]](#)
- Manav, s., çağli, a., & yilmaz, m. (2019). Güreş develerinde bazı vücut ölçümleri, baş, testis sıcakliklari ile davranışsal özelliklerin ve güreş performanslarının karşılaştırılması. *Fen ve sağlık bilimleri*, 107.
- Mensah, M. L., Komlaga, G., Forkuo, A. D., Firempong, C., Anning, A. K., & Dickson, R. A. (2019). Toxicity and safety implications of herbal medicines used in Africa. *Herbal medicine*, 63(5), 1992-0849.
- Mok, C. K. P., Zhu, A., Zhao, J., Lau, E. H., Wang, J., Chen, Z., Zhuang, Z., Wang, Y., Alshukairi, A. N., & Baharoon, S. A. (2021). T-cell responses to MERS coronavirus infection in people with occupational exposure to dromedary camels in Nigeria: An observational cohort study. *The Lancet Infectious Diseases*, 21(3), 385-395. [\[Crossref\]](#)
- Swelum, A. A., El-Saadony, M. T., Abdo, M., Ombarak, R. A., Hussein, E. O., Suliman, G., ... & Abd El-Hack, M. E. (2021). Nutritional, antimicrobial and medicinal properties of Camel's milk: A review. *Saudi Journal of Biological Sciences*, 28(5), 3126-3136. [\[Crossref\]](#)
- World Health Organization. (2019). *WHO global report on traditional and complementary medicine 2019*. World Health Organization.
- Yadav, A. K., Kumar, R., Priyadarshini, L., & Singh, J. (2015). Composition and medicinal properties of camel milk: A review. *Asian Journal of Dairy and Food Research*, 34(2), 83-91. [\[Crossref\]](#)