






ORIGINAL RESEARCH ARTICLE

Oxidative Stress Biomarkers Activities and Histological Changes in African Catfish (*Clarias gariepinus*) Exposed to Carwash Wastewater

Nafiu, Shafiu Abdullahi¹ , Usman, Lawal Usman² , Mohammed, Jibril Madaki³ , Alkali, Zahraddeen Dahiru⁴ , and Ibrahim, Ado Adamu⁵ 

^{1,4}Department of Life Sciences, Kano State Polytechnic, Kano- Nigeria

²Department of Biology, Umaru Musa Yar'adua University Katsina, Nigeria

^{3,5}Department of Environmental Science and Management Technology, College of Administration, Management and Technology, Potiskum, Yobe State, Nigeria

ABSTRACT

The study evaluated the acute toxicity of vehicle wastewater on African catfish (*Clarias gariepinus*). With a weight range of 250–275.5g and a mean length of 23.5-28.5cm, 150 post-juvenile catfish were purchased from Dalar Kifi Fish Farm BUK New site road, Kano State, and acclimated in a tank for 14 days. Fish were exposed to different vehicle wastewater concentrations of 0.0, 20, 40, 60, and 80% v/v with 5-level exposure concentrations during the acute test (96 hours) in a Completely Randomized Design (CRD) employing renewal bioassay. The acute bioassay showed that the LC₅₀ for the wastewater was 56 percent by volume at 96 hours. Compared to the control, the exposed fish exhibited abnormal swimming, erratic opercular movement, reflex loss, mucus secretion, increased air gulping with an increase in wastewater concentration. Except for water temperature, Biochemical Oxygen Demand (BOD) and pH, the remaining physicochemical parameters were not within the WHO/FAO recommended Standard. The order of concentrations of the heavy metal in the wastewater was Cu > Pb > Cd > Cr > Ni. Antioxidant biomarker activities showed that Glutathione reductase (GSH) reduced in the same manner while Catalase (CAT) and Superoxide dismutase (SOD) activities rose considerably (P<0.05) in the liver and gill tissues. Histopathological changes observed in gill tissues were as follows: Hyperplasia, necrosis, primary and secondary lamellae distortion, and epithelial thickening distortion. Hepatic cell breakdown, fatty degeneration, cellular infiltration, localized fibrosis, and cellular necrosis were all visible in the liver tissues. It can be inferred that changes in the histology and activity of the oxidative stress enzymes in fish tissues after exposure to wastewater harmed the experimental fish. As a result of their effects on fish and other non-target aquatic biota, it is advised that the competent authorities create initiatives to reduce the indiscriminate discharge of untreated vehicle wash wastewater.

ARTICLE HISTORY

Received August 7, 2022

Accepted September 29, 2022

Published September 30, 2022

KEYWORDS

Clarias gariepinus, Histology, carwash wastewater, Oxidative stress biomarker, Toxicity

© The authors. This is an Open Access article distributed under the terms of the Creative Commons Attribution 4.0 License (<https://creativecommons.org/licenses/by-nc/4.0/>)

INTRODUCTION

Water contamination from home and industrial waste is getting worse every day in many industrialized nations (Abdullahi *et al.*, 2021). Washing your car to get rid of dirt and other contaminants require the use of large volume of water and applying chemicals, including ammonium compounds, surfactants, detergents, oil and grease, fuel, and other potentially harmful substances that end up in the water bodies (Zaneti *et al.* 2012). When such contaminants are released into the aquatic ecosystem, the water quality is impacted, which inferred how well the water can be used for domestic, agricultural, industrial, and recreational reasons (Elias *et al.*, 2020). It

has been observed that using wastewater for irrigation alter the water quality in aquatic environments, leading to an ecological imbalance (Reeta *et al.*, 2020). The contaminants have a wide range of effects and stressors on aquatic flora and fauna, especially fishes, as well as the potential for bioaccumulation (Sayyadi *et al.*, 2022). Fish are frequently employed to evaluate the quality of the water, and as a result, they act as bioindicators of water pollution (Ahmad *et al.*, 2018). Reactive oxygen species (ROS) are produced as a result of heavy metal buildup and other xenobiotics in fish tissue, which leads to oxidative stress (Ullah *et al.*, 2019).

Correspondence: Nafiu, S. A.; Department of Life Sciences, Kano State Polytechnic, Kano, Nigeria.

✉ shafiu.nafiu@kanopoly.edu.ng; +234(0)8064042006

How to cite: Nafiu, S. A., Usman, L. U., Mohammed, J. M., Alkali, Z. D and Ibrahim, A. A. (2022). Oxidative Stress Biomarkers Activities and Histological Changes in African Catfish (*Clarias gariepinus*) Exposed to Carwash Wastewater. UMYU Scientifica, 1(1), 49 – 59. <https://doi.org/10.47430/usci.1122.008>

Many mammalian species, especially aquatic animals like fish, have defense systems to mitigate the effects of ROS (Ezenwosu *et al.*, 2021). The biochemical alterations caused by heavy metal poisoning in aquatic creatures have been studied using biomarkers of oxidative stressors such as the antioxidant defense enzymes including superoxide dismutases (SOD), catalase (CAT), GSH, and Glutathione transferase (GST). Pro-oxidant and antioxidant levels are out of balance during oxidative stress, which causes free radicals to stimulate a variety of physiological processes, including cellular transcriptional pathways (Akinwande *et al.*, 2016). For assessing the harmful effects on fish target tissues both *in vivo* and *in situ* investigations as well as histological studies have been used (Samson, 2015). Due to their proximity to aquatic environments, fish among other aquatic biota are usually at the receiving end of numerous xenobiotics (Nafu and Ibrahim, 2019). As a result, modifications to their structure and function act as a biomarker for aquatic contaminants (John *et al.*, 2021). In light of the aforementioned, a study was carried out ascertain how African catfish's histology and oxidative stress biomarker enzyme activities were affected by vehicle wash wastewater exposure.

MATERIALS AND METHODS

Sampling site and Collection of Water samples

Composite car wash wastewater was collected from the outlet of carwash premises located at Kofar Ruwa Motor Park, Kano (12°01'44.9"N, 8°29'56.8"E). The samples were collected in triplicate. Following the procedure used by Saiyadi *et al.* (2022), the water samples were promptly evaluated for the following physicochemical parameters using a multifunction water testing kit (Digital Water tester Model no. EZ-9909-SP). These parameters include color, pH, Total Dissolved Solid (TDS), Dissolved Oxygen (DO), Biochemical Oxygen Demand (BOD), and electrical conductivity.

Analysis of heavy metals in water samples

A total of 80 mL each of the composite car wash water and control water (borehole) samples were combined and put into a 250 mL beakers. After adding 10 mL of HNO₃ and heating it to 100 °C, the samples were allowed to evaporate to roughly 50 mL before another 5 mL of HNO₃ was added and heated continuously until it reached a final volume of about 15 mL. The digested samples were filtered using Whatman number1 filter paper and made up to a final volume of 20 mL after with distilled water according to the method adopted by Saiyadi *et al.* (2022). The concentrations of cadmium, chromium, nickel, manganese, and lead were examined in the water using Micro Plasma Atomic Emission Spectrometry (MP-AES Agilent 4200 model) at Centre for Dry Land Agriculture Laboratory, Bayero University Kano.

Source of fish used in the experiment

One hundred and fifty (150) post-juvenile catfish (*Clarias gariepinus*) in total, with average weight range of 250–275.5 g and a mean length of 23.5–28.5 cm were purchased from the Dalar Kifi Fish Farm in Langel Town along the BUK new site, Kano State, Nigeria (11°98'98.1"N, 8°36'95.4"E). The fish were kept in a 500 L black plastic tank that was regularly refilled with borehole water. They were acclimated for two weeks (14 days) in a semi-static 28 °C environment in a laboratory setting. A 2 mm pelletized meal (42% crude protein) made by UAC Vital Fish Feed Nigeria Plc was given to them twice at 5% of their body weight. To lessen the stress on the fish, the experimental water was drained off every 24 h, and feeding was stopped 24 h before the toxicity test

Experimental design

The experiment was conducted at the Biological Sciences Department of Bayero University Kano following the OECD (2013) guidelines in a 100 L plastic containers. The experimental and control groups of ten (10) *C. gariepinus* were exposed to 5-level of exposure to the variable concentration of the carwash wastewater in a completely randomized design (CRD). By combining wastewater with borehole water, four test solutions (20, 40, 60, and 80 percent v/v) were created, while the fifth (zero percent), which only contained borehole water, served as the control as adopted by Adeboyejo *et al.* (2013).

Acute Toxicity Experimentation

The approach outlined by the OECD (2013) and Reddy (2018) was used to calculate the definitive concentration for the range-finding test on the wastewater. An acute toxicity test was carried out to determine the 96-h LC₅₀ of the wastewater. The test was run for 12, 24, 48, 72, and 96 hours in triplicate. To get the LC₅₀ values, mortality from wastewater exposure was collected at 24 h intervals.

Observation of behavioral responses

After being exposed for thirty (30) min, the fish's behaviors, including irregular swimming, air gulping, loss of reflex and mucous secretion were monitored as reported by Rakesh and Kumar (2019). When there was no discernible movement or no reaction to light poking, fish were deemed to be dead.

Analysis of oxidative stress biomarkers

Two (2) g of the liver and gill tissues were removed and rinsed in 5 mL of isolation buffer containing 100 mM Tris-HCl at a pH of 7.20 to lessen blood stains. After which were blended with a mortar and a pestle on ice as adopted by Mandeep and Rajinder (2017). The homogenate was centrifuged at 12000g for 5 min to separate and reveal the cellular contents. SOD (BC0170), CAT (BC0200) and GSH (BC1170) kits manufactured by Solarbio Life Science, supplied by Plasma Diagnostic Laboratory, Tarauni, Kano State were used. According to the manufacturer's instructions, 150 µL of each tissue homogenate was mixed with 1 mL of the extraction

reagent and thoroughly mixed on an ice bath. The mixture was centrifuged at 8000 rpm and 4 °C for 10 minutes to obtain the supernatant. A glass cuvette was used to collect exactly 90 µL of the mixture, which was then carefully mixed with 240 µL of reagent I, 6 µL of reagent II, and 30 µL of reagent V, and 180 µL of reagent III. After that, 180 µL of distilled water was added, and it was let to stand at 4°C for 30 minutes. The mixtures of each tissue sample were tested for the activity of SOD, CAT and GSH using Spectrophotometer (UV-6300PC double beam model) at Biochemistry Department of Bayero University, Kano.

Histopathological analysis of *C. gariepinus* tissues

The procedure described by Auwioro (2010) was used to run the fish tissue biopsies at the Histopathology Laboratory at Aminu Kano Teaching Hospital in Kano, Nigeria. The fish were euthanized with 40% ethyl alcohol before having their gills and livers removed for histological analysis. Fish tissues were dehydrated with increasing grades of alcohol, fixed with 10% formal saline, cleaned with toluene, and embedded with molten paraffin wax. The tissues were sectioned using a microtome to obtain 5 µm sections. Haematoxylin and Eosin staining was performed and the tissues inspected under a microscope (LEICA DM 750 model) and photographed using an HD camera (LEICA ICE 50 model).

Statistical analysis

Table 1: Mean values of physicochemical parameters of carwash wastewater obtained from kofar ruwa motor park area, Kano state, Nigeria

Parameters	Carwash waste water	Control	Standard
Water temperature (°C)	31.40±0.11	27.7±0.23	<40
DO (mg/L)	3.10±0.10	6.1±0.23	5.0-9.0
BOD (mg/L)	4.70±1.01	2.2±0.45	3.0-6.0
TDS (mg/L)	787±0.10	125.7±0.25	<500
Electrical Conductivity (µS/cm)	2153±2.21	387.0±3.15	<1000
Turbidity (NTU)	42.50±0.92	27.6±1.12	<25
pH	8.90±1.01	7.3±0.01	6.0-9.0

WHO/FAO (2018)

According to the findings of the measurements of heavy metal concentrations, Pb had the highest mean concentration (3.56 mg/L), followed by Cu (3.16 mg/L), Cd (1.98), Cr (0.97 mg/L), and Ni (0.88 mg/L) in the car wash wastewater (Table 2). The order of concentrations of

Using SPSS version 20.0, probit analysis was utilized to determine the mortality profile (LC₅₀) of the experimental fish. The Duncan multiple range test with a probability level of 5% was used to compare the means after a one-way analysis of variance (ANOVA) was performed to ascertain the impact of different waste water concentrations on the activity of the oxidative stress enzymes in *C. gariepinus*.

RESULTS

Physicochemical and Heavy metals parameters

The mean values of physicochemical parameters of the waste water revealed that temperature, Dissolved Oxygen, Biochemical Oxygen Demand, Total Dissolved Solids, Electrical conductivity, turbidity, and ph had the following: 31.4 ± 0.11 °C, 3.10 ± 0.10 mg/L, 4.70 ± 1.01 mg/L, 787 ± 0.10 mg/L, 2153 ± 2.21 µS/cm, 42.5 ± 0.92 NTU and 8.90 ± 1.01 respectively. While the control water sample had the following mean values of temperature (27.7 ± 0.23 °C), DO (6.1 ± 0.23 mg/L), BOD (2.2 ± 0.45 mg/L), TDS (125.7 ± 0.25 mg/L), EC (387.0 ± 3.15 µS/cm), turbidity (27.6 ± 1.12 NTU), and pH (7.3±0.01) respectively.

the heavy metal in the wastewater was Cu > Pb > Cd > Cr > Ni. None of the heavy metals was detected in the control water samples.

Table 2: Mean values of heavy metals of car wash wastewater obtained from Kofar ruwa Motor Park Area, Kano State, Nigeria

Parameters	Vehicle Wastewater	Control	Standard
Cu (mg/L)	3.56±0.84	BDL	0.05
Pb (mg/L)	3.16±0.21	BDL	0.10
Cr (mg/L)	0.97±0.30	BDL	0.05
Ni (mg/L)	0.88±0.11	BDL	0.05
Cd (mg/L)	1.98±0.94	BDL	0.01

BDL: Below Detection Limit, WHO (2011)

Behavioral responses in the experimental fish

The fish exposed to carwash waste water displayed irregular swimming, loss of reflex, hyperventilation, incessant jumping, and discoloration at the beginning of the treatment, which increased with the concentrations of the wastewater (Table 3).

Table 3: Behavioral changes recorded in *Clarias gariepinus* during 96h exposure to carwash waste water

Exposure Time (h)	Concentration (%)	Erratic swimming	Reflex loss	Hyperventilation	Inconsistent jumping	Discoloration
24	0.00	-	-	-	-	-
	20	-	-	-	-	-
	40	-	-	+	-	-
	60	-	-	+	-	-
	80	+	+	+	+	-
48	0.00	-	-	-	-	-
	20	-	-	-	-	-
	40	-	-	-	-	-
	60	-	-	+	+	-
	80	+	+	+	+	-
72	0.00	-	-	-	-	-
	20	-	-	-	-	-
	40	-	-	-	-	-
	60	-	+	+	+	-
	80	+	+	+	+	-
96	0.00	-	-	-	-	-
	20	-	-	-	+	-
	40	-	-	+	+	-
	60	+	+	+	+	-
	80	+	+	+	+	-

Key: - = absent + = Present

Acute Toxicity (96hr LC₅₀) for Vehicle Waste Water

Table 4 presents the fish survival and cumulative mortality profile on exposure to various test concentrations of vehicle wastewater. Depending on the exposure time (24, 48, 72, and 96 h), the number of living and dead fish were

counted. The highest fish mortality was documented in the carwash wastewater concentration which was 80%, at 0%, while there was no mortality noted in the control throughout the trial (Table 3).

Table 4: Data on cumulative mortality profile of *Clarias gariepinus* exposed to varying concentrations of carwash wastewater for 96h

Exposed conc. (%v/v)	log conc.	No. of exposed fish	No. of live fish at different duration (hr)				% survival	% mortality	Probit
			24	48	72	96			
0.00	0.000	10	0	0	0	0	100	0	0.00
20.0	1.301	10	0	0	0	0	100	0	0.00
40.0	1.602	10	1	0	0	0	90	10	3.72
60.0	1.778	10	2	2	1	1	40	60	5.25
80.0	1.903	10	3	2	2	1	20	80	5.84

Figure 1 shows the LC₅₀ corresponding to each waste water concentration. Based on the converted probit analysis, the 96-h LC₅₀ values were 56%. An increase in death rate is shown as carwash waste water concentration

rises, as presented by the linear relationship between probit mortality and concentration, which showed a positive correlation of r² = 0.9846.

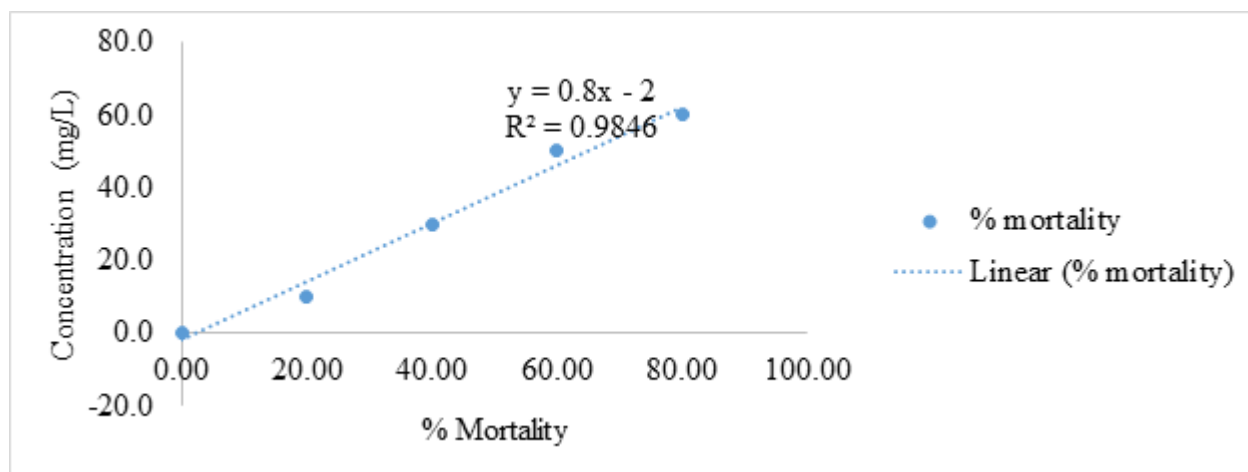


Fig 1: Mean lethal concentration LC₅₀ of *C. gariepinus* challenged with varying carwash waste water concentrations at 96hr

Activities of oxidative stress biomarkers

Superoxide Dismutase (SOD) Activity

Fish gill and liver tissues exposed with the highest dose of 80% carwash wastewater had a significant ($p < 0.05$) increased in the SOD activity of 4.85 ± 1.00 Unit/mg protein and 5.13 ± 0.32 Unit/mg protein respectively. While lower activity of 1.53 ± 0.22 Unit/mg protein (gills) and 1.41 ± 0.01 Unit/mg protein (liver) were obtained in the control sample (Table 4).

Glutathione Reductase Activity (GR)

The GR had lower activity lower in the liver and gill tissues subjected to the highest concentrations (80% v/v), with 17.50 ± 1.02 nmol/min/mg protein and 9.70 ± 0.11 nmol/min/mg protein, respectively. The control samples of liver tissue and gills had the highest activity, measuring 46.80 ± 0.01 nmol/mg protein and 34.1 ± 0.21 nmol/min/mg prot, respectively. The GR activity differed significantly ($p < 0.05$) between the tissues as well as the concentrations.

Catalase (CAT) activity

The CAT activity was higher in the liver tissues subjected to the highest concentrations (80%) of 79.45 ± 0.71 Unit/mg protein while lowest activity of 37.21 ± 2.10 Unit/mg protein was recorded in the control samples. The CAT activity differed significantly ($p < 0.05$) in a concentration dependent manner. However, CAT activity showed no significant difference ($P > 0.05$) in the gills tissues between the exposed and control fish. Their values increase with an increase in the carwash waste water concentrations from 47.56 ± 0.01 Unit/mg protein to 83.78 ± 0.66 Unit/mg protein respectively.

Histopathological Changes

The primary and secondary lamellae of the gills in the control samples had normal architecture according to the histological study of the gill tissues, with no obvious pathological changes (Figure 2; Plate I a). At 20% (v/v) carwash wastewater the experimental fish developed primary lamella hyperplasia after the 96 h experimental exposure (Figure 2; Plate I b).

Table 4: Acute of oxidative stress enzymes activity in *C. gariepinus* challenged to carwash waste water

Organ	Conc mg/L/ Activity	GR (nmol/mg protein)	SOD (unit/ mg protein)	CAT (Unit/mg protein)
Liver	0.00	46.80 ± 0.01^b	1.41 ± 0.01^a	37.21 ± 2.10^b
	20	32.4 ± 1.03^a	2.27 ± 0.17^a	43.81 ± 1.05^b
	40	28.3 ± 0.01^a	2.74 ± 0.01^a	47.54 ± 0.13^a
	60	21.50 ± 0.01^a	3.98 ± 0.12^b	54.90 ± 0.01^a
	80	17.50 ± 1.02^a	5.13 ± 0.32^b	79.45 ± 0.71^a
Gills	0.00	34.1 ± 0.21^a	1.53 ± 0.22^b	47.56 ± 0.01^a
	20	31.4 ± 0.01^a	1.65 ± 0.78^a	57.32 ± 1.5^a
	40	28.3 ± 0.11^b	3.80 ± 0.07^a	61.65 ± 0.54^a
	60	13.10 ± 0.93^a	4.71 ± 0.91^a	76.45 ± 1.03^a
	80	9.70 ± 0.11^b	4.85 ± 1.00^a	83.78 ± 0.66^a

Mean values with different superscripts alphabets in a column differed significantly ($P < 0.05$)

Lifting of the main lamellae and epithelial thickening distortion were the alterations noted at 40% carwash wastewater. (Figure 2; Plate I c). Additionally, at a

concentration of 60% carwash wastewater, secondary lamellae curling and degeneration were observed (Figure 2; plate I d). Necrosis and the merging of primary and

secondary lamellae were seen at 80% carwash wastewater (Figure 2; Plate I e).

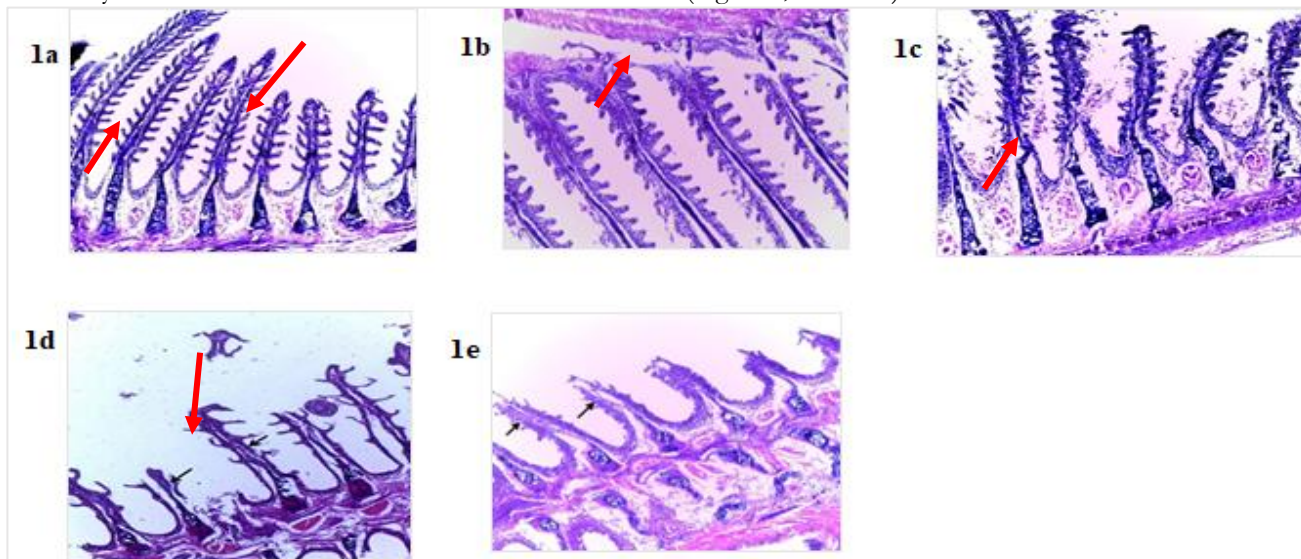


Figure 2. Histopathological changes in gills of *C. gariepinus* treated with carwash wastewater: Photomicrograph of control sample gills tissue of *C. gariepinus* indicating normal gill architecture of the lamellae in the control group without any discernable change (Plate 1a). hyperplasia of primary lamella (Plate 1b). lifting of the primary lamellae and epithelial thickening distortion (Plate 1c). curling and degeneration of secondary lamellae (Plate 1d). necrosis, fusion of primary and secondary lamellae (Plate 1e). (H&E, mag x 100).

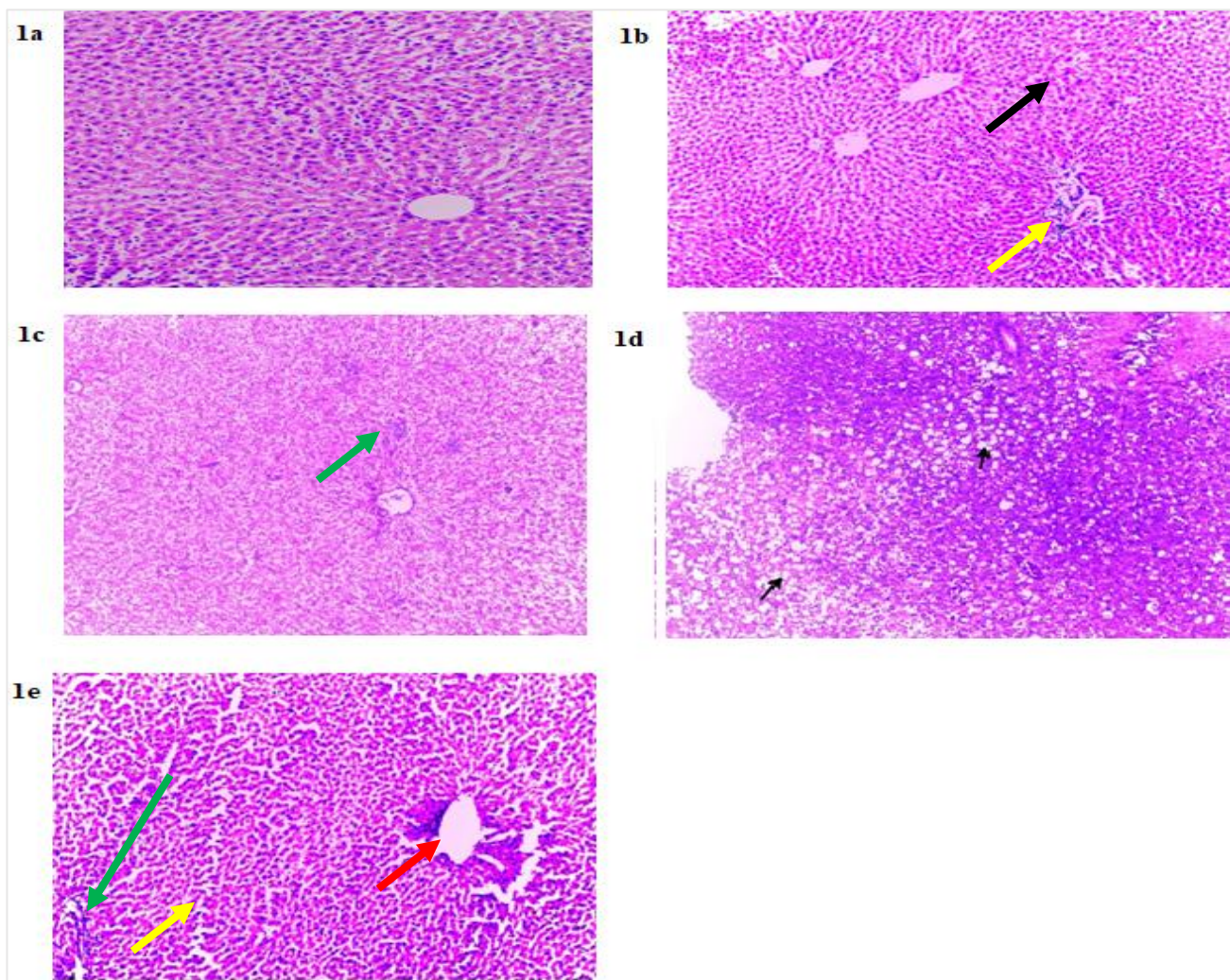


Figure 3. Histopathological changes in livers of *C. gariepinus* treated with carwash wastewater: Liver tissue revealed normal architecture with hepatocyte morphology intact, vacuolation, and hepatic cord structure in the control fish samples without any discernible alterations (Plate Ia). At 20% of the treated fishes had fatty degeneration (black arrow) and focal fibrosis (yellow arrow) (Plate Ib). Liver tissue showed hepatocytes necrosis at 40% concentration (green arrow) (Plate Ic). Focal fibrosis (red arrow) and Cellular Infiltration (black arrow) at 60% concentration of wastewater ((plate Id). At 80% of vehicle wastewater concentration, liver tissue showed hepatocyte necrosis (green arrow), fatty degeneration (yellow arrow), and central vein distortion (red arrow) (Plate Ie). (H & E mag x 100).

The liver tissue in the control fish samples had normal architecture, normal hepatocyte morphology, normal vacuolation, and normal hepatic cord structure (Figure 3; Plate Ia). The treated fish developed cytoplasmic degeneration and fatty degeneration at 20% v/v carwash wastewater (Figure 3; Plate Ib). At a 40% carwash wastewater dosage, liver tissue exhibited necrosis and blood vessel congestion (Figure 3; Plate Ic). Focal fibrosis Cellular Infiltration with a 60% carwash wastewater concentration (Figure 3; Plate Id). Hepatocyte necrosis and central vein degeneration were visible in the liver tissue at an 80% carwash wastewater concentration (Figure 3; Plate Ie) (H & E mag x 100).

DISCUSSION

Important indicators for controlling physiological processes and the dispersion of aquatic biota are the physicochemical characteristics of water (Jamila and Sule, 2020). Many metabolic processes in an organism are influenced by the temperature of the water (Habu *et al.*, 2021). The wastewater was somewhat alkaline, as indicated by the pH value of 8.9 in the current study, which may affect a variety of physiological activities in the exposed experimental fish (FAO/WHO, 2018). The amount of dissolved ions in water is regulated by electrical conductivity. The value recorded in carwash wastewater of 2153 $\mu\text{S}/\text{cm}$ is higher than the FAO/WHO (2018) recommended value of 1000 $\mu\text{S}/\text{cm}$ for a typical freshwater body. The higher mean conductivity observed in this study suggested that more ions inflow and other dissolved elements from carwash wastewater are present than the recommended values. Organic contamination has been linked to high BOD levels in water (Rabiu *et al.*, 2018). When significant amounts of wastewater are dumped into bodies of water, the enhanced aerobic microbial decomposition of organic materials may result in hypoxic conditions, which may have several effects on the physiology of aquatic animals (Adamu *et al.* 2016). According to Shawai *et al.* (2018), the amount of dissolved oxygen found in the vehicle wastewater sample is less than the recommended level of 5 mg/l, which makes it impossible to sustain the experimental animals. The turbidity of the carwash wastewater was higher than the FAO/WHO (2018) recommended limit of 25 NTU for freshwater bodies on the surface. The waste water's high turbidity implies that it contains some dissolved compounds that pose a hazard to the experimental fish species' ability to survive (Nafiu *et al.*, 2020). The dissolved salts in the water may have contributed to the elevated TDS readings by altering the metabolic processes of the experimental fish

(Sayyadi *et al.*, 2022). According to the measured levels of the heavy metals, Copper had the highest level (3.56 mg/L), whereas Nickel had the lowest level (0.88 mg/L). $\text{Cu} > \text{Pb} > \text{Cd} > \text{Cr} > \text{Ni}$ was the order in which the amounts of heavy metals in the carwash waste water dropped. The elevated levels of Cu and Pb found are consistent with Nafiu and Ibrahim's (2017) findings in tannery effluent. According to Ishaq *et al.* (2011), the cupric Cu^{2+} form of copper, which is frequently present in water sediment, is what causes copper's detrimental effects. Numerous heavy metals are known to attach to crucial structural proteins, enzymes, and nucleic acids in a cell, changing how those components operate (Abdulhamid *et al.*, 2022)

The experimental fish showed a variety of stressful abnormalities throughout the 96 h exposure, which was particularly noticeable in fish exposed to the highest concentrations of vehicle wastewater. These abnormalities included inconsistent jumping, hyperventilation, generalized body weakness, loss of reflex, and erratic swimming. According to Rakesh and Kumar (2019) these behavioral modifications are a reaction to the chemical components contained in the vehicle wastewater. According to Roopadevi and Somashekar (2012), hyperventilation measurements revealed respiratory impairment caused by the exposed fish's gills being exposed to vehicle wastewater. The highest carwash waste water concentrations result in general body weakening and final 100 percent mortality at 96 h. This could be caused by oxygen depletion in the body of the experimental fish, which interfered with their capacity to jump out of the wastewater and leads to their death (Barboza *et al.*, 2018). The 96 h LC_{50} value of 56% v/v found in the current investigation indicated that the vehicle wastewater is poisonous to the experimental fish. As in earlier research by Alimba *et al.* (2015) in abattoir wastewater (96 h LC_{50} = 6.28%), mortality in the current finding was concentration-dependent.

One of the enzyme preventing the body from the state of oxidative stress in living organisms is superoxide dismutase (SOD) (Mandeep and Rajinder, 2017). It changes superoxide radicals in the mitochondria and peroxisomes into H_2O_2 , which is then converted by CAT into inert oxygen and water (Ullah *et al.*, 2019). With an increase in carwash wastewater concentrations, SOD activity increased dramatically in *C. gariepinus'* gills and liver tissues in a concentration-dependent manner when compared to control. By converting the radicals to H_2O_2 , SOD may have responded to the production of superoxide anions, increasing its activity. According to Ezenwosu *et al.* (2021) an increased level of superoxide radical production within

the cells may have caused an increase in SOD activity, which in turn led to the enhanced level of SOD activity seen in the exposed fish tissues.

The scavenger enzyme catalase promotes the breakdown of H₂O₂ into O₂ and H₂O. SOD and CAT activity are thus a direct indicator of the antioxidant status of aquatic organisms like fish (Mandeep and Rajinder, 2017). When compared to control fish during the research period, exposed fish had elevated CAT readings. The high CAT activity in the liver and gills had a varying trend throughout the exposure period, increasing at the highest concentration. The increase in CAT activity values might be caused by oxy-radical generation by inorganic and other organic salts in the water, which was mediated by the carwash wastewater (Reddy, 2018). Similar observation was reported by Reddy (2018). The input of superoxide radicals that forced the CAT to set up an effective compensatory pathway after exposure to the contaminants may also be responsible for the elevated activity observed in the present finding.

When compared to control, the current finding showed a significant reduction in GR in all of the liver and gills investigated. GR has been regarded as an antioxidant involved in the breakdown of many hazardous chemicals during detoxification (Blanco *et al.*, 2014). By interacting with oxygen species/nitrogen species, it protects and stabilizes cell membranes from lipid peroxidation (Reddy, 2018). According to Akinwande *et al.* (2016), the lower GR activity found in the fish tissues when compared to controls may be caused by wastewater toxicity. According to Oluwatosin *et al.* (2016), it might be because GSH were acting as more of a barrier against lipid peroxidation within the cell compartment. Like in other organisms, antioxidant enzymes like GR, SOD, and CAT aid in neutralizing the damaging effects of ROS in fish.

At various exposure concentrations of the carwash wastewater, which increases in a concentration-dependent way, several histological abnormalities were examined in the liver of experimental fish. Focal fibrosis, hepatocyte necrosis, fatty degeneration, central vein distortion, and cellular infiltrations were found after assessing the clinical symptoms. Liver's participation in the metabolism and detoxification of toxic compounds may be responsible for the fatty degeneration in the tissue examined. Udotong (2015) reported a similar findings in tilapia fish treated with Fe, Pb, and Cu. Mutsapha *et al.* (2017) described cellular infiltration of the hepatocytes of liver as a symptom of a degenerative process, which implies metabolic imbalance owing to exposure to waste water.

The gill architecture, which is essential for life processes including osmoregulation, respiration, and detoxification, had undergone mild to severe changes as a result of the histopathological changes that have been observed in gill tissues. Due to the proximity to the external environment, any changes in the water's quality have an impact on the gills' ability to function normally (Abalaka, 2015). When compared to the control, the various wastewater

concentrations employed in this investigation revealed changes. These include primary lamella hyperplasia, epithelial thickening distortion, secondary lamellae curling, and degenerating, lamellae fusion, and necrosis. The nonspecific changes of hyperplasia and epithelial thickening distortion are thought to be related to exposure to pollutants (Mubarak *et al.*, 2021). According to Adeboyejo *et al.* (2013), these modifications may cause gill tissues to malfunction and caused the experimental fish to suffocate. Curling and degeneration of the secondary lamellae may be related to physiological changes in fish caused by toxicant ingestion or a defense mechanism used by the organism to stop pollutants from entering via the gill surface (Ravanaiah *et al.*, 2010; Mustapha *et al.*, 2017). The investigated lamellar fusion and necrosis might have resulted from cellular growth, which also caused lamellar fusion. Hypoxia is caused by the reduced surface area for oxygen binding caused by the lamellar fusion, which also reduces the oxygen distance between water and blood (Elias, *et al.*, 2020). Similar observation was reported by Adeboyejo *et al.* (2013) in *C. gariepinus* exposed to industrial waste. The present finding also concurred with Ravanaiah *et al.* (2010) who reported vacuolization, fusion of secondary gill lamellae and degraded cells in *Tilapia mossambica* subjected to industrial pollutants. Peebua *et al.* (2008) also examined lamellar fusion, epithelial lifting, dilatation, and congestion in the blood vessels of the gill lamellae in fish exposed to copper solution.

CONCLUSION AND RECOMMENDATIONS

The wastewater's water quality characteristics (physicochemical composition and heavy metal levels) exceeded the approved Standard for Surface Freshwaters. The experimental *C. gariepinus* experienced oxidative stress and histological damage on exposure to the vehicle waste water in a dose-dependent manner. This suggests that waste water's components are possible toxins that can change tissue indices and have a variety of pathological effects on fish bodies. The nearby aquatic ecosystem and its biota may be in danger if these waste water are discharged carelessly into the water body. Therefore, it is advised that competent regulatory organizations develop a comprehensive strategy for reducing aquatic pollution. Given the detrimental effects on numerous non-target organisms, strict pollution mitigation rules should be passed and implemented to prevent the illegal release of vehicle wastewater into water bodies.

LIMITATIONS

The experimental water used during the research was only borehole water and 96 h exposure duration was maintained for acute toxicity. Among the groups of biomarkers examined, only SOD, CAT and GR were tested considering their significance in free radicals scavenging.

REFERENCES

Abagale, F. K., Sarpong, D. A., Ojediran, J. O., Osei-Agyemang, R., Shaibu, A. G. and Birteeb, P. T.

- (2013). Heavy Metal Concentration in Wastewater from Car Washing Bays Used For Agriculture In The Tamale Metropolis, Ghana. *International Journal of Current Research*, 5 (6): 1571-1576.
- Abalaka, S.E. (2015). Heavy metals bioaccumulation and histopathological changes in *Auchenoglanis occidentalis* fish from Tiga dam, Nigeria. *J. Environ. Health Sci. Engin.* 13: 1-8. <https://doi.org/10.1186/s40201-015-0222-y>
- Abdulhamid, Z., Agbaji, E. B., Yakubu, M. and Musah, M. (2022). Assessment of Heavy Metals Content in Selected Vegetables from Irrigation Farms in Minna, Nigeria. *Savanna Journal of Basic and Applied Sciences*, 4(1): 17-26.
- Abdullahi, N., Igwe E.C., and Dandago, M.A. (2021). Heavy metals contamination through consumption of contaminated food crops. *Moroccan Journal of Agricultural Sciences*, 2: 52–60.
- Adamu, G.A, M.S Sallau, S.O. Idris (2016). Surface and drinking water quality monitoring of Thomas reservoir, Kano State, Nigeria. *International Science Index, Chemical and Molecular engineering*, 10(12). 1439-1443.
- Adeboyejo, O.A., Fagbenro, O.A., Adeparusi, E.O. and Clarke, E.O. (2013). Acute toxicity of industrial effluents from agbara environs of ologe lagoon on early life stages of African catfish *Clarias gariepinus*. *American Journal of Research Communication*, 1(3): 50-60.
- Ahmad, M. K., Nafiu, S. A., Baba, H. A., Rashida, I. U., Zakariyya, M. and Abubakar, S. (2018). Heavy metals bioaccumulation in tissues of *Tilapia zillii* as Indicators of water pollution in Kafinchiri Reservoir, Kano – Nigeria. *Bayero Journal of Pure and Applied Sciences*, 11(1): 443 – 450. <https://doi.org/10.4314/bajopas.v11i1.70S>
- Akinwande, A. A; Abdulkadir, J.O and Adesina, B.T. (2016). Oxidative Stress and Antioxidant Response in the Giant African Catfish (*Heterobranchus bidorsalis* Geoffroy Saint-Hilaire, 1809) under Chronic Paraquat Exposure. *Nigerian Journal of Fisheries and Aquaculture*, 4(2): 30 – 37.
- Badamasi, I. (2014). Distribution of Stomach Food Content of Fish Species Collected from Industrial Waste Water Effluents. A Case Study of Jakara Dam. *International Journal of Innovation and Technology*, 5(2): 124-129. <https://doi.org/10.7763/IJIMT.2014.V5.499>
- Ali, A. F, H. Abdullahi, A. I. Tanko, S. K. llah (2018). Water Supply and Sanitation Challenges in Dala Local Government Area of Kano State, Nigeria. *Dutse Journal of Pure and Applied Sciences*, 4(2): 604 – 611. <https://doi.org/10.2495/WM140271>
- Ali, A. F., and R.J. Young, (2014). An Assessment of Groundwater Contamination around a Solid Waste Disposal Site in Kano, Nigeria. *Waste Management and the Environment*, 7(180) 317 – 323.
- Alimba, C. G., Ajayi, E. O., Hassan, T., Sowunmi, A. A and Bakare, A.A. (2015). Cytogenotoxicity of abattoir effluent in *Clarias gariepinus* (Burchell, 1822) using micronucleus test. *Chinese Journal of Biology*, 97:221-234. <https://doi.org/10.1155/2015/624524>
- Alshalabi, L., Shaaban, Z. and Kasasbeh, B. (2006). Data Mining: A Preprocessing Engine. *Journal of Computer Science*, 2(9):735-739. <https://doi.org/10.3844/jcssp.2006.735.739>
- Blanco, A.T., Anderica, R.A.C and Pendraza, C. J. (2014).. New insights into antioxidant strategies against paraquat toxicity. *Free Radicals Research*, 48: 623-640.
- Butu, A.W., Bello, M.I., Atere, P.M and Emeribe, C.N. (2018). Assessment of Heavy Metals Pollution and Their Bioaccumulation In *Tilapia* Fish (*Oreochromis niloticus*) Tissue From Thomas Dam, Kano State, Nigeria. *Nigerian Journal of Agriculture, Food and Environment*, 15(2): 89-103.
- Devi, Y. and Mishra, A. (2013). Histopathological alterations in gill and liver anatomy of freshwater, air breathing fish *Channa Punctatus* after pesticide hilban® (Chlorpyrifos) treatment. *Advances in Bioresearch*, 14(2) 57-62.
- Elias, N.S; Abouelghar G.E; Sobhy, H.M; El Miniawy, H.M; Elsaiedy E.G.(2020). Sublethal effects of the herbicide thiobencarb on fecundity, histopathological and biochemical changes in the African catfish (*Clarias gariepinus*). *Iranian Journal of Fisheries Sciences*, 19(3): 1589-1614.
- Ezike, C. O; Felix, O. E; Nicholas, C. U and Godwin, E. O. (2019). Haematology, Oxidative Stress and Micronuclei Frequency of *Clarias gariepinus* Exposed to Glyphosate based Herbicide Glycot GBHG. *International Journal of Advanced Fisheries and Aquatic Science*, 4(1): 106-121. <https://doi.org/10.23953/cloud.ijafas.442>
- Hadi, A. A and Alwan, S.F. (2012). Histopathological changes in gills, liver and kidney of fresh water fish, *Tilapia zillii*, exposed to aluminum. *Int. Journal of Pharmacy and Life Sci*, 3: 2071-2081.
- Habu, M. A., Bawa, U and Musa, S.I. (2021). Health Risk Assessment and Heavy Metal Bioaccumulation in Vegetables Irrigated with Waste Water in Kano State, Nigeria. *Notulae Scientia Biologicae Journal*, 13: 1–8.
- Hadi AA, Alwan SF (2012).Histopathological changes in gills, liver and kidney of fresh water fish, *Tilapia zillii*, exposed to aluminum. *Int. J. Pharm. Life Sci*. 3: 2071-2081.
- Ibrahim, S. and Nafi'u, S. A. (2017). Invitro effect of tannery effluents on seed germination and growth performance of maize (*Zea mays*), spinach (*Spinacia caudatus*) and lettuce (*Lactuca sativa*). *International Journal of Applied Biological Research*, 8(1): 160 – 173.
- Imam, T.S. (2012). Assessment of Heavy Metals Concentrations in the Surface Water of Bompai-Jakara Drainage Basin, Kano State, Northern

- Nigeria. *Bayero Journal of Pure and Applied Sciences*, 5: 103–108. <https://doi.org/10.15835/nsb13110890>
- Ishaq, S. E., Rufus, S. A and P.A. Annune, P. A. (2011). Bioaccumulation of Heavy Metals in Fish (*Tilapia Zilli* and *Clarias gariepinus*) Organs from River Benue, North- Central Nigeria. *Pakistan Journal of Analytical and Environmental Chemistry*, 12(1&2): 25-31.
- Jamila T.S., and Sule S.Y. (2020). Assessments of Quality Index of River Getsi Irrigation Water in Kano Metropolis, Nigeria. *International Research Journal of Pure and Applied Chemistry*, 21: 8–16. <https://doi.org/10.9734/irjpac/2020/v21i330156>
- Kaur, R. and Dua, A. (2015). 96 h LC₅₀, behavioral alterations and histopathological effects due to wastewater toxicity in a freshwater fish *Channa punctatus*. *Environmental Science and Pollution Research*, 22(7): 5100-5110. <https://doi.org/10.1007/s11356-014-3710-1>
- Kavy, G. K. S.,Jadesh, M and Kulkarni, R. S. (2016). Hematology and serum biochemical changes in response to change in sauna Kawaji and Tokarawa Concentration in fresh water fish, *Notopterus Notopterus*, *World Scientific News*, 32: 49-59. <https://doi.org/10.18052/www.scipress.com/II.NS.49.19>
- Lawrence, E. and Temiotan, E., (2010). Histopathological effects of Gammalin 20 on *Clarias gariepinus*. *Applied and Environmental Soil Science*, 1: 1-8. <https://doi.org/10.1155/2010/138019>
- Mandeep, K and Rajinder, J. (2017). Oxidative stress response in liver, kidney and gills of *ctenopharyngodon idellus* (cuvier & valenciennes) exposed to chlorpyrifos, *MOJ Biology and Medicine*, 1:103-112. <https://doi.org/10.15406/mojbm.2017.01.00021>
- Mazumber, D and Mukherjee, S. (2011). Treatment of automobile service station wastewater by coagulation and activated sludge process. *International Journal of Environmental Science and Development*, 2, 64 –69. <https://doi.org/10.7763/IJESD.2011.V2.98>
- Mustafa, S.A., Al-Faragi, J.K., Salmanm, N.M and Al-Rudainy, A.J. (2017). Histopathological alterations in gills, liver and kidney of common carp, *Cyprinus carpio* l. Exposed to lead Acetate. *Adv. Anim. Vet. Sci.* 5(9): 371-376.
- Nafiu, S. A and Ibrahim, S. (2017). Seasonal Dynamics of Zooplankton Composition and Abundance in Thomas Dam, Dambatta, Kano State, Nigeria. *Bayero Journal of Pure and Applied Sciences*, 10(1):268 – 276. <https://doi.org/10.4314/bajopas.v10i1.40>
- Nafiu, S. A., Zakariyya, M., Hassan, Z.Y and Ahmad, M. K. (2020). In Vitro Effect Of Pharmaceutical Effluent on Haematology and Biochemical Responses In African Catfish (*Clarias gariepinus*). *FUDMA Journal of Sciences*, 4(4):391 – 400. <https://doi.org/10.33003/fjs-2020-0404-495>
- OECD (2013). Organization of Economic Co-operation and Development. Guidance Document on Acute Oral Toxicity. OECD Publishing; pp. 1–27
- Oladeji, S. O. (2020). Evaluation of physicochemical parameters in wastewater from Muhammad Ayuba dam in Kazaure, Jigawa state, Nigeria. *Archives of Agriculture and Environmental Science*, 5(4): 482-488. <https://doi.org/10.26832/24566632.2020.050408>
- Peebua, P., Kruatrachue, M., Pokethitiyook, P. and Singhakaew, S. (2008). Histopathological alterations of Nile tilapia, *Oreochromis niloticus* in acute and subchronic alachlor exposure. *Journal of Environmental Biology*, 29 (3): 325-331.
- Putshaka J. D., Akyengo O., Yakubu A., Adejube A. A. H (2015). Bioaccumulation of Heavy Metals in Fish (*Tilapia zilli*) and Bullfrog (*Pyxicephalus edulis*) from River Challawa, Kano State Nigeria. *International Journal of Ecological Science and Environmental Engineering*, 2(4): 30-34.
- Rabiu, H. D., Umar, L. M., Sulaiman, I., Madina, M., and Abubakar, A. I. (2018). Assessment of the Water Quality of Watari Dam, Kano State Using Selected Physicochemical Parameters. *International Journal of Advanced Academic Research*, 4(5): 62-77.
- Ravanaiah, G. and Narasimha murthy, C.V. (2010). Impact of aquaculture and industrial pollutants of nellore district on the histopathological changes in the gill of fish, *Tilapia mossambica*. *Ind jour. Comp. Animal. Physiol.*, 28 (1):108-114.
- Reddy, P.B. (2018). Study on the Toxic Effects of Waste Water in Cat Fish (*Heteropneustes Fossilis*). *Life Sciences International Research Journal*, 5(2): 165-174.
- Reddy, P.B., (2016). Study of pollution induced oxidative stress in a cat fish (*Mystus tengara*). *European Journal of Biomedical*, 3(12): 595-600.
- Reeta, R., Subodh, S. D. B., Gurung, B. K., S and Ram, D. S. (2020) Assessing the impacts of vehicle wash wastewater on surface water quality through physico-chemical and benthic macroinvertebrates analyses, *Water Science*, 34:1, 39-49. <https://doi.org/10.1080/11104929.2020.1731136>
- Srivastava, B. and Reddy, P.B. (2017). Lipid peroxidation and DNA damage as biomarkers of pollution induced oxidative stress (OS) *Life Sciences International Research Journal*, 4(1): 194-198.
- Shawai, S. A. A., Nahannu, M.S., Abdulkadir, S and Minjibir, S.A. (2018). Evaluation of Physicochemical Parameters and Some Heavy Metals in Water Samples Used For Irrigation Purpose along River Tatsawarki In Tarauni L.G.A, Kano. *International Journal of Scientific Research in Chemical Sciences*, 5(6):1-4.
- Saiyadi, A. R., Mustapha, K. U., Ado, I. M and Nafiu S. A. (2022). Assessment of Heavy Metal Concentrations as Indicator of Pollution in *Clarias gariepinus* (African Catfish) of Warwade Reservoir, Dutse, Jigawa State-Nigeria. *Dutse Journal of Pure*

- and Applied Sciences*, 8(1a): 10-21.
<https://doi.org/10.4314/dujopas.v8i1a.2>
- Udotong, J.I.R. (2015). Histopathological changes in liver and muscle of tilapia fish from QIRE exposed to concentrations of heavy metals. *Int. J. Biol. Biomol. Agr. Food Biotechnol. Engin.* 9: 659-662.
- Ullah, S., Zhongqiu, L, Amina, Z., Muhammad, Z. U. A and Mirza, M.F. A.B. (2019). Biomarkers of pyrethroid toxicity in fish. *Environmental Chemistry Letters*, **1**: 1-28.
- Zaneti, R., Etchepare, R and Rubio, J. (2012). More environmentally friendly vehicle washes: Water reclamation. *Journal of Cleaner Production*, 37, 115–124.
<https://doi.org/10.1016/j.jclepro.2012.06.017>