



A Review on Current Trend in the Management of Necrotizing Fasciitis

*Abdullahi Samaila¹ and Musa Sani Kaware²

¹Department of Pharmacology, College of Medical Sciences, Umaru Musa Yar'adua University, Katsina, Nigeria.

²Department of Community Medicine, Umaru Musa Yar'adua University, Katsina, Nigeria.

Corresponding author: abuuismaeel@gmail.com, mobile: 08031817444.

Abstract

Necrotizing fasciitis an inflammatory and infectious disease condition affecting the fascia with the secondary involvement of soft tissues and skin. This infection is associated with progressive necrosis of any of the layers in the soft tissue compartment. The infection is commonly polymicrobial and sometimes methicillin resistant staphylococcal infection. It affects various parts of the body in males, females and paediatric age groups. It is a worldwide disease of public health concern and the mortality rate could be up to 100% if not diagnosed and treated early. It is classified based on the causative microorganisms and part of the body affected. There are four important types based on microbiological classification as follows; 1) Type 1 necrotizing fasciitis (polymicrobial infection), 2) type 2 (Monomicrobial Gram-positive organisms), 3) type 3 (Gram-negative monobacteria typically marine-related organisms). 4) Type 4 (Fungal infection). The diagnosis of necrotizing fasciitis comprises of multidisciplinary approach to include Microbiologists, Histopathologists, as well as Medical and Surgical teams. The clinical evaluation of the patient and laboratory analysis of the samples obtained from the wound site, will guide for appropriate treatment of the infection. The management includes immediate resuscitation of the patient, early administration of broad-spectrum parenteral antibiotics to cover for gram-positive, gram-negative, aerobes and anaerobic organisms such as cephalosporins, penicillins, quinolones, vancomycin, clindamycin and metronidazole. Empirical antibiotic treatment is considered before the result of culture and sensitivity is out Aggressive wound debridement in theatre provides a favourable outcome.

Key words: Necrosis, Fascia, Inflammatory, Subcutaneous and Microbial.

INTRODUCTION

Necrotizing fasciitis (NF) is a rapidly progressing, inflammatory infection of the fascia with the secondary involvement of skin, subcutaneous tissues and muscle (Morgan, 2010). The infection is highly associated with very quick progressive necrosis of any of the layers in the soft tissue compartment, such as dermis, subcutaneous tissue, superficial fascia, deep fascia and muscle (Mulcahy and Richardson, 2010). NF is a severe form of soft tissue infection. NF occurred sporadically in last century, mainly during the wartime and it was Monobacterial, but recently its occurrence in civilian population is increasing and it is mostly polymicrobial and sometimes methicillin resistant *staphylococcal* infection (Miller *et al.*, 2005). Several terminologies were used to describe necrotizing fasciitis (NF) such as hospital gangrene, *streptococcal* gangrene, acute dermal gangrene, Fournier's gangrene, suppurative fasciitis, necrotizing erysipelas and synergistic necrotizing cellulites. Wilson, (1952) gave the term 'necrotizing fasciitis' to describe the disease and still it is the preferred

terminology in these days, as it describes the most consistent and key features of the disease due to characteristic necrosis of the fascia related to the lesion. The high morbidity and mortality associated with the disease makes it an emergency. Early debridement provides a favourable outcome. Hence, it is a surgical emergency. More than 90% of NF patients may also need intensive care and organ supportive therapy and this makes it a medical emergency. Up to 46% of patients with necrotizing fasciitis may need limb amputation or disarticulation (Cheung *et al.*, 2009).

Necrotizing fasciitis is becoming a common disease condition globally. The prevalence is high in developing countries especially northern Nigeria, as evidenced by increased number of hospital admission from the disease. It is associated with increase morbidity and mortality. The causative organisms are polymicrobial and sometimes difficult to treat, particularly in cases of multidrug resistant bacteria.

Having a good and broad knowledge of current trend in handling cases of necrotizing fasciitis including disciplinary approach in its management, will certainly help in reducing the burden, morbidity and even mortality of the disease.

The main aim of this review is to evaluate the current trend in handling a patient with necrotizing fasciitis.

The specific objectives are:

1. To understand the specific causes of the necrotizing fasciitis and possible risk factors.
2. To know the mode of development of the disease and most affected parts of the body.
3. To realize how to identify the disease and give suitable antibiotic therapies.
4. To reduce morbidity from the disease as much as possible.
5. To update young practitioners on how to handle a patient with necrotizing fasciitis.

EPIDEMIOLOGY

Necrotizing fasciitis is a worldwide infection of public health concern with greater prevalence especially in pre-antibiotic era. (Ozturk, *et al.*, 2005).It has been predicted that 13 cases of necrotizing fasciitis per million of populations are hospitalized every year, and 20-30% of these patients die from the disease. The mortality rate could be up to 100% if not diagnosed and treated early (Misiakos *et al.*, 2014). In United State America, the NF occurs in 4.3 per 100,000 of the population. In United Kingdom 500, new cases of necrotizing fasciitis were estimated per year. NF commonly occurs in male, and has a male to female ratio of 3:1; it affects the extremities more often than other parts of the body (Shaikh *et al.*, 2012). According to Shaikh *et al.*, (2012) 54% of patients could have NF of the extremities while Anaya *et al.*, (2005) reported 58.7% of patients with NF of the extremities. Necrotizing fasciitis of the perineum and genitalia occurs in 20%, while chest, flanks, shoulder as well as hip and

gluteal region are affected in about 8.5% of the patients. Abdominal and cervical necrotizing fasciitis are uncommon (about 5.3% and 2.1% occurs respectively). NF is also frequent in paediatric and neonatal age group. It hardly affects the scalp (Shaikh *et al.*, 2012).

However, according to the study conducted by Legbo and Shehu, (2005) at Sokoto, Northern Nigeria, NF affects up to 70.9% of the extremities in adults (lower limb 54.2% and upper limb 16.7%) whereas in children up to 34.4% of both extremities were affected. Almost 20.8% of cases were seen in the perineum. They also reported that most of the NF cases were detected in children compared to adult. Similarly, Obimakinde *et al.*, (2012) reported 12 confirmed cases of cervicofacial NF out of 48 patients admitted at university college hospital Ibadan, Nigeria. Male to female ratio was 4:8 and the age range of the study subjects was 42 to 83 years. However, previous studies on cervicofacial necrotizing fasciitis from South-Western Nigeria by Ndukwe *et al.*, (2002) and Obiechina *et al.*, (2001) revealed higher male preponderance of 5:2 and 5:3 in the order given.

CLASSIFICATION

Necrotizing fasciitis is categorized based on part of the body involved and the type of microorganisms causing the infection. It is known as idiopathic necrotizing fasciitis when it occurs without any triggering factor.

According to the part of the body involved, it is classified as:

- a) Cervicofacial necrotizing fasciitis (when it affects head and neck)
- b) Abdominal necrotizing fasciitis (Meleney’s gangrene)
- c) Fournier’s gangrene (Perineum and genitalia necrotizing fasciitis)

Based on the causative organisms, it is categorized into four types, (Table 1).

Table 1: Microorganisms causing Necrotizing Fasciitis

S/N	Type of NF	Causative Organisms
1	Type I necrotizing fasciitis	Synergistic polymicrobial infection
2	Type II necrotizing fasciitis	Monobacterial gram-positive organisms
3	Type III necrotizing fasciitis	Gram-negative monobacteria (marine organisms)
4	Type IV necrotizing fasciitis	Fungal infection.

Source: El-Menyar *et al.*, (2017).

in addition, is synergistic infection.

Type I Necrotizing Fasciitis

Is a polymicrobial, consisting of mixed growth of anaerobes and aerobes, bowel flora derived

Some of the common microorganisms involved include *E.coli*, *Pseudomonas* spp., *Bacteroides* spp., *Vibrio* spp., *Staphylococcus* spp., and *Streptococcal* spp. This type of NF affects the perineum and trunk (Irwin and English, 2013; Goh *et al.*, 2014). It is a common type of necrotizing fasciitis. It frequently affects patients with diabetes mellitus. It accounts for 70-90% of cases (Misiakos *et al.*, 2014).

Type II Necrotizing Fasciitis

This is a Monobacterial; the causative organism will be Group A/B-haemolytic streptococcus (*Streptococcus Pyogenes*) either alone, or in combination with the *Staphylococcus aureus*. Even though *S. aureus* singly can cause the type II infection, which secretes toxins that cause destruction of the leukocyte and tissue necrosis. It is difficult to manage, particularly when it is caused by the methicillin-resistant *S. aureus* (MRSA), which is found in 10-30% of all cases. Type II NF is skin or throat derived infection. It commonly affects the extremities, and occurs in young and immunocompetent patients following a small surgical wound or prolonged use of Non-Steroidal Anti-inflammatory drugs (NSAID). Typically associated with toxic shock syndrome and multiple organ dysfunctions. The outcome is unfavourable (Misiakos *et al.*, 2014; Shaikh *et al.*, 2012).

Type III Necrotizing Fasciitis

It is caused by gram-negative and marine-related bacteria, such as *Vibrio* specie (*Vibrio vulnificus*) and *Aeromonas hydrophila* (found in fresh water and soil) or *Clostridium* specie (*C. perfringens*), especially among drug abusers. The portal/route of entry for this type is a punctured wound, caused by fish or marine insects or cut injury exposed to the seawater. It is also related to external injuries and surgical wounds. A hyper acute infection (fulminant) can easily cause septic shock and Multi Organ Dysfunction Syndrome (MODS) in less than 24 hour of the injury. Up to 100% mortality may occur when not recognized early. Most people at risk are farmers (Misiakos *et al.*, 2014; Shaikh *et al.*, 2012).

Type IV Necrotizing Fasciitis

Type IV NF is caused by fungal infection (*Candida* spp. *Mucor*, *Rhizopus* and *Zygomycetes*). It can spread rapidly to severe form of the disease. It occurs in immunocompromised or poorly traumatized patients. (Shaikh *et al.*, 2012; Misiakos *et al.*, 2014).

The organisms isolated in the study of Legbo and Shehu, (2005) at Sokoto, Northern Nigeria were *P. aeruginosa* > *S. aureus* > *Klebsiella* > *Streptococcus Pyogenes* > *E. coli* among adult patients. *S. aureus* > *Streptococcus Pyogenes* > *E. coli* > *P. aeruginosa* > *Klebsiella*, in children (Table 2).

Table 2: Commonly isolated bacteria associated with necrotizing fasciitis in Northern Nigeria.

Isolated Bacteria	Total (%)
<i>S. aureus</i>	60.7
<i>P. aeruginosa</i>	51.8
<i>Klebsiella</i>	50.0
<i>Streptococcus Pyogenes</i>	46.2
<i>E. coli</i>	37.5

Source: Legbo & Shehu, (2005).

Risk Factors

Diabetes mellitus is the most common risk factor for necrotizing fasciitis accounting for about 57% (Cheung *et al.*, 2009). Hypertensive heart disease (25% Patients), heart diseases (15%), chronic obstructive diseases (5.3%) and brachial asthma (2.1%), 11.7% of minor trauma, 10.6% surgical procedures, non-steroidal anti-inflammatory drugs (NSAIDs) and insect bite also considered as aetiological risk factors for the development of necrotising fasciitis. Others include age > 50yrs, malnutrition, intravenous drug users, chronic liver disease, chronic kidney disease and malignancies (Shaikh, 2006 and Shaikh *et al.*, 2012).

Pathogenesis

The main site of infection is superficial fascia, then the infection spread through the fascial planes without involvement of skin, this is known as horizontal spread. The horizontal spread starts with initial trivial injury where the bacteria invade the superficial fascia, proliferate and produce hyaluronidase enzymes (Seal, 2001). These enzymes cause degradation and necrosis of the fascial layers, which provides more favourable atmosphere for bacterial growth, and uncontrolled spread of the infection. That is why patients become sicker without significant local manifestations. As the disease progresses, the vertical spread of infection ensues, which leads to the involvement of skin, subcutaneous tissue, deeper fascia and muscles (Seal, 2001).

As soon as the necrosis of the superficial fascia take place, there will be infiltration of the leucocyte in to the deeper fascia, dermis, thrombosis and suppuration of veins and arteries passing through the fascia. This results in occlusion of the dermal nutrient vessel, progressive ischemia and gangrene of the overlying skin (Seal, 2001).The streptococcus organism as in type II NF produces a large number of virulence factors and exotoxin. The virulence factors damage host tissues by inactivating polymorphonuclear cells. The exotoxin augments the virulence and accelerates progression of the infection (Sarani *et al.*, 2009). Streptococcus and staphylococci produce surface antigen M1, M3, exotoxins A, B, C, streptolysin O, and super antigens. An M protein increases adherence ability of these bacteria, which aids microorganisms in avoiding the phagocytosis. Exotoxin A and B causes loss of vascular integrity leading to capillary leakage and tissue oedema. The effect of these virulent factors and exotoxin is ultimately rapid spread of infection especially in type II necrotizing fasciitis. (Shaikh *et al.*, 2012; Seal, 2001). Therefore, such patients often present with the toxic shock syndrome (TSS) and multiorgan dysfunction syndrome (MODS).

Diagnosis

The diagnosis of necrotizing fasciitis comprises both clinical and laboratory aspects. The clinical diagnosis involves mainly clinical evaluation of the patient while the laboratory diagnosis involves analysis of the samples obtained from the wound site in the laboratory. This will certainly guide for appropriate treatment of the infection.

Clinical Diagnosis

The clinical diagnosis is based on history of symptoms and signs of the disease at patient’s presentation. Similarly, the affected part of the body (Figures 1-4) and history of risk factors/comorbidity will help in determining the likely type of necrotizing fasciitis clinically. The triad of symptoms are local pain, swelling, and erythema (Goh *et al.*, 2014).The pain is disproportionate to swelling and erythema. Fever is considered as a common symptom,

followed by clinical findings on examination such as Tachycardia (pule rate >100bpm), andtachypnea (RR>20/min) and systolic hypotension (SBP<100 mmHg). These clinical findings and erythematous skin can be useful in the diagnosis of necrotizing fasciitis (Shimizu & Tokuda, 2010). Other important signs include skin tenderness, sclerosis, bullae (which are initially serous and subsequently become haemorrhagic) and necrosis at the site of the infection (Frazee *et al.*, 2008).

However, sometimes the patients may not present with the above clinical features but rather two groups of presentations can be evident, that is to say early and late presentations. In early presentation, patients present with pain, fever, erythema, local warmth, skin sclerosis and oedema.In fulminant form of the disease, there will be features of severe septic shock and multiple organ dysfunction syndrome along with soft tissue necrosis. In this situation, the general condition of the patient worsens rapidly within a short period. In the late presentation, the clinical course of the infection is slow which may take days to weeks. Patients present more often with features of septic shock or multiorgan dysfunction syndrome such as high temperature, tachycardia, hypotension, tachypnea, elevated white blood cell count,electrolyte derangement, acidosis and coagulopathy. Other symptoms of systemic toxicity include apathy, dehydration, confusion, dizziness, diarrhoea, nausea, vomiting, weakness, and malaise (Roje *et al.*, 2011). There will be haemorrhagic bullae, loss of skin sensation, crepitus (due to gas formation indicative of anaerobic organism especially *C. per- fringens*) and extensive skin necrosis at the affected site (Table 3).

It is important to note that, some patients might be taking analgesics, steroids and antibiotics before presentation and this can lessen body temperature and conceal fever. Therefore, absence of fever or elevated temperature does not mean to exclude the diagnosis of necrotizing fasciitis (Goh *et al.*, 2014; Shimizu & Tokuda, 2010).

Table 3: Stages of necrotizing fasciitis based on cutaneous manifestations

Stage 1 (early)	Stage 2 (intermediate)	Stage 3 (late)
Erythema	Serous bullae/blisters	Haemorrhagic bullae
Swelling	Skin fluctuance	Loss of skin sensation
Warm	Skin induration	Crepitus
Tenderness		Extensivenecrosis with dusky, blue/purple skin discolouration to gangrene

Source: Wang *et al.*, (2007).

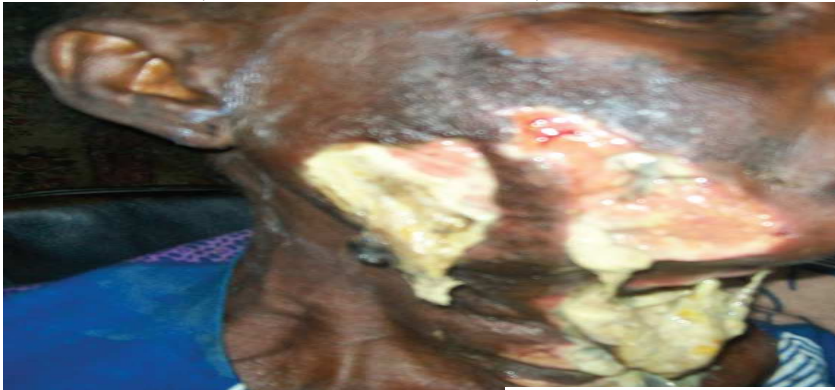
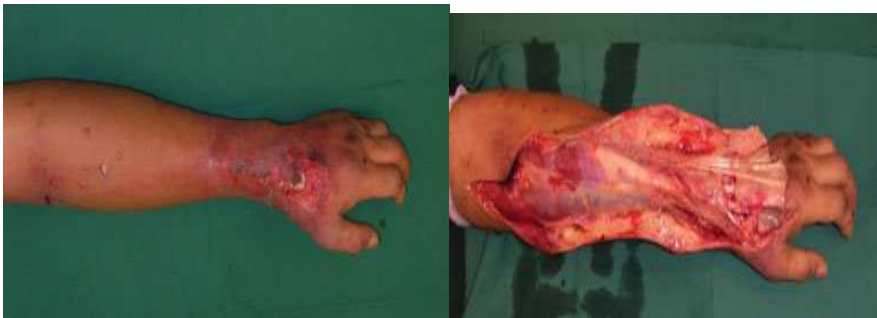
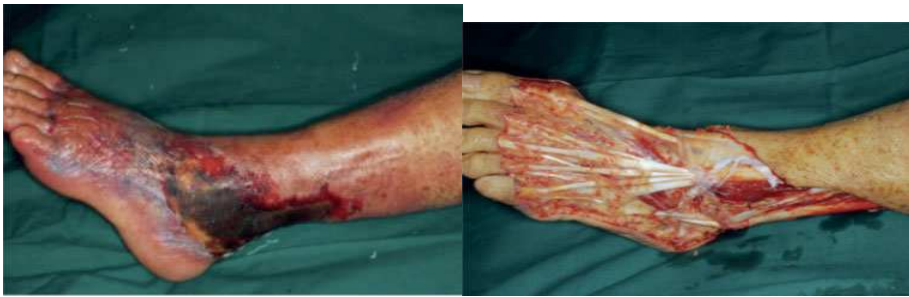Figure 1: Cervicofacial Necrotizing fasciitis. Necrotizing fasciitis affecting face and neck of an adult patient with necrotic tissues in the wound.

Source: Obimakinde *et al.*, (2012).



A.

B.



C

D

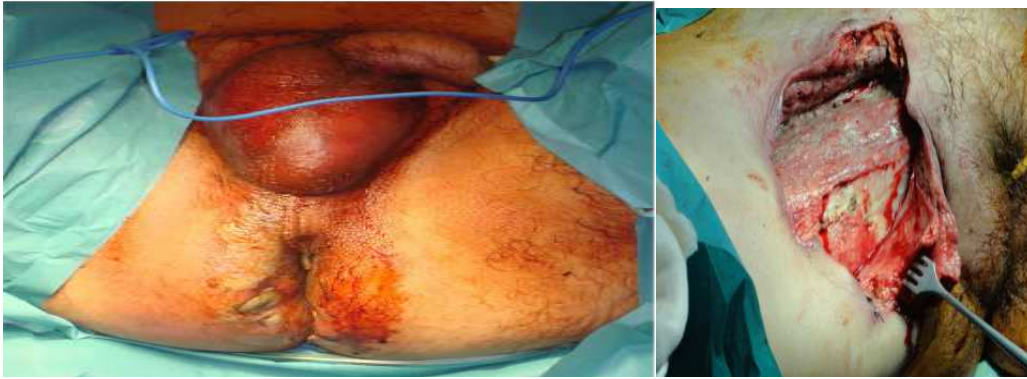
Figure 2: Necrotizing fasciitis of the upper and lower limbs. Source: Goh *et al.*, (2014).

Figure (A) shows necrotizing fasciitis of left upper limb before surgical debridement while figure (B) after the debridement in the theatre. Figure (C) shows necrotizing fasciitis of the left lower limb before surgical debridement while figure (D) after the debridement.

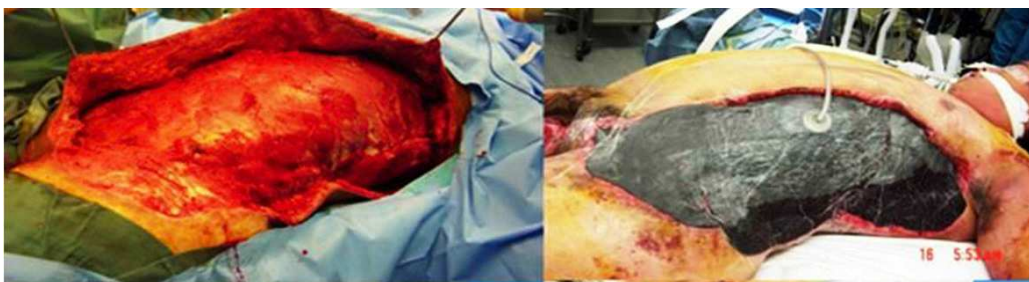

Figure 3: Abdominal and chest necrotizing fasciitis. Source: El-Menyar *et al.*, (2017).

The figures above depict abdominal necrotizing fasciitis (Meleney's gangrene) extending to the chest after surgical debridement. The second figure shows application of vacuum assisted compression (VAC), to aid in wound healing by aspirating exudate of serous fluid and pus collection from the wound site.



A (Male patient)

B (Female patient)

Figure 4: Fournier's gangrene. Source: Misiakos *et al.*, (2014).

Figure (A) shows Fournier's gangrene of a male patient. That is necrotizing fasciitis of the perineum affecting perianal and scrotal region being prepared for surgical debridement in the theatre. Figure (B) shows necrotizing fasciitis of a female patient affecting the right perineal area close to labium majus during surgical debridement.

Laboratory Diagnosis

The laboratory diagnosis depends on findings from laboratory investigations such as Full blood count and differentials to reveal evidence of anaemia and leucocytosis. Serum electrolyte, urea and creatinine (E/U/Cr) to show if there is renal impairment and electrolyte derangement. Blood sugar level to know if the patients are diabetics. Urinalysis to detect glycosuria. C- reactive protein level as a marker for inflammatory process (Misiakos *et al.*, 2014). Liver function test (LFT) and Clotting profile, to show evidence of multiorgan dysfunction. Gram staining, Blood culture and Wound swab microscopy, culture and sensitivity

(MCS) for identification of causative organism and guide to treatment. Microbiological diagnosis is obtainable in about 75% of patients with necrotizing fasciitis. This can be achieved when blood and pus samples are taken correctly before and during operation. Positive blood culture is obtainable in 25% of cases whereas cultures taken from the wound site during surgical debridement can be positive in up to 80% of patients (Misiakos *et al.*, 2014). Laboratory Risk Indicator for Necrotizing Fasciitis (LRINEC) score is a predictive tool for the diagnosis of necrotizing fasciitis using laboratory parameters (Table 4).

Table 4: Laboratory Risk Indicator for Necrotizing Fasciitis (LRINEC) Score.

Variable (units)	Score points
C-Reactive Protein (CRP) (mg/L)	
<150	0
>150	4
White blood cell count (10 ⁹ /l)	
<15	0
15-25	1
>25	2
Haemoglobin (g/dl)	
>13.5	0
11-13.5	1
<11	2
Serum Sodium (mmol/L)	
≥135	0
<135	2
Serum Creatinine (mg/dl)	
≤1.6	0
>1.6	2
Serum Glucose (mg/dl)	
≤180	0
>180	1

Source: Wong & Heng, (2004).

A LRINEC score of ≥ 6 is suspicious of necrotizing fasciitis (has a positive and negative predictive values for necrotizing fasciitis of 92% and 96% respectively) while a LRINEC score of ≥ 8 (has a positive predictive value $>92\%$ and specificity of 95%) is strongly indicative of necrotizing fasciitis (Shaikh *et al.*, 2012; Irwin and English, 2013).

Bedside tests and radiological investigations should be performed in patients with equivocal LRINEC score (≥ 6 but <8). Finger test is a bedside procedure performed by making a 2 cm incision on the infected area under local anaesthesia down to the deep fascia, followed by blunt and gentle finger dissection in to the wound. Appearance of typical “dishwater pus” (offensive, brown-coloured pus), absence of bleeding and absence of tissue resistance to finger dissection are positive findings related to necrotizing fasciitis. The pus is for microscopy, culture and sensitivity to guide in diagnosis and treatment. Incisional biopsy for histology is another important bedside test, it is performed by making a deep surgical cut over the necrotic area down to the fascial level to remove about 1 cm of soft tissue that will be stained and cultured. In necrotizing fasciitis, the histological investigation will reveal vasculitis, thrombosed blood vessels, necrosis, polymorphonuclear infiltrate and some microbes. The combination of surgical exploration and microbiological and

histopathological analysis of 1cm³ of the soft tissue is the gold standard for confirming diagnosis (Morgan, 2010; Misiakos *et al.*, 2014).

Radiological Diagnosis

Radiological investigations can be helpful in equivocal cases of necrotizing fasciitis. A plain radiograph can show gas formation in the soft tissue indicative of infection by *Clostridium specie* (Ruiz-Tovar *et al.*, 2012). Computerized tomography (CT) scan shows the extent of inflammation, tissue necrosis, fascial swelling and gas formation while magnetic resonance imaging (MRI) provides better diagnostic accuracy than CT. Ultrasound scan (USS) may also be useful in some cases (Nagano *et al* 2008).

Differential Diagnosis

The differential diagnosis of necrotizing fasciitis includes cellulitis, Clostridial myonecrosis, deep vein thrombosis, toxic shock syndrome, acute epididymitis and orchitis (Edlich, 2017; Irwin and English, 2013).

Complications

Some of the complications of necrotizing fasciitis are septicaemia, anaemia, contracture/joint stiffness, tetanus and chronic osteomyelitis, pressure sores, multi-organ dysfunction syndrome and wound infected with methicillin resistant *Staphylococcus aureus* (Legbo and Shehu, 2005; Roje *et al.*, 2011).

Treatment

The successful treatment of necrotizing fasciitis involves both medical and surgical interventions (Yadav *et al.*, 2012) as follows:

Medical Treatment

The medical treatment comprises of supportive and parenteral antibiotic therapy. It is always important to make sure that the patient's airway is patent and can breathe well. The supportive treatment depends on the condition of the patient at presentation. It includes immediate resuscitation with intravenous fluid when the patient is dehydrated with or without shock, correction of electrolyte derangement, correction of anaemia with blood transfusion, correcting hyperglycaemia and nutritional support. (Misiakos *et al.*, 2014; Roje *et al.*, 2011) Bedside wound dressing can be done while preparing the patient for debridement in theatre.

Broad-spectrum antibiotics should be started early to cover for Gram positive, Gram-negative aerobes and anaerobic organisms. An empirical combination of triple antibiotics such as Penicillin G, Gentamycin, and Clindamycin (Roje *et al.*, 2011) or Clindamycin, Meropenem, and Vancomycin particularly in suspected case of Methicillin Resistant *Staphylococcus aureus* (Irwin and English, 2013). These antibiotics can be administered early at presentation that might be adjusted when Gram stain, culture and sensitivity results are out. Another alternative is to combine at least three antibiotics from the classes of broad-spectrum antibiotics such as cephalosporins, aminoglycosides, clindamycin, penicillins and metronidazole. (Hernández *et al.*, 2017).

Similarly, the antibiotics can be given according to the suspected type of necrotizing fasciitis. For type 1 NF consider ampicillin or ampicillin-sulbactam + 3rd / 4th generation cephalosporins + clindamycin/metronidazole. For type 2 NF: 1st or 2nd generation cephalosporins/penicillins+ clindamycin/metronidazole. In cases where MRSA is suspected vancomycin is added to the combination above. For type 3 NF: penicillins + clindamycin for suspected *Clostridial* infection. Third generation cephalosporins + tetracyclines

(doxycycline or minocycline) in suspected case of *vibrio* infection. For type 4 NF: use of antifungals such as amphotericin B or fluoroconazoles (Misiakos *et al.*, 2014).

The use of hyperbaric oxygen in the management of necrotizing fasciitis is controversial not yet proven beneficial to patients but rather may even delay the necessary medical and surgical interventions. Hence, not recommended by the Infectious Diseases Society of America (IDSA). However, the use of intravenous immunoglobulin (IVIG) was recommended by IDSA in patients with *Streptococcus Pyogenes* infection (Hernández *et al.*, 2017). Because it contains antibodies which neutralize streptococcal antigen. It is given as 2g/kg infusion stat which can be repeated as a second dose after 24 hours when necessary (Irwin and English, 2013).

Surgical Treatment

The surgical treatment is the aggressive surgical debridement in the theatre this is the most important aspect in the management of necrotizing fasciitis. The main aim of debridement is to remove all the necrotic tissue (necroctomy) and infected fascia (fasciectomy) at once to prevent subsequent and unnecessary going back to theatre (See Figure 5 & 6) (Wong *et al.*, 2008).

Post-operative wound care including regular dressing is very important to enhance wound healing. The use of vacuum- assisted closure (VAC) therapy was recommendable worldwide by numerous surgeons due to its effectiveness in wound closure. A VAC device comprises of a sterile, open-cell foam sponge that is positioned in the wound, the size is adjustable to the wound size. It is then covered with a transparent adhesive drape to create an airtight environment. The sponge is linked to a portable vacuum pump by means of non-collapsible tube. Evacuation is applied to the sponge using the pump, which creates continuous negative pressure (See figure 3 above) (Misiakos *et al.*, 2014). Most patients may need skin grafting or release of contracture by the plastic surgeons.

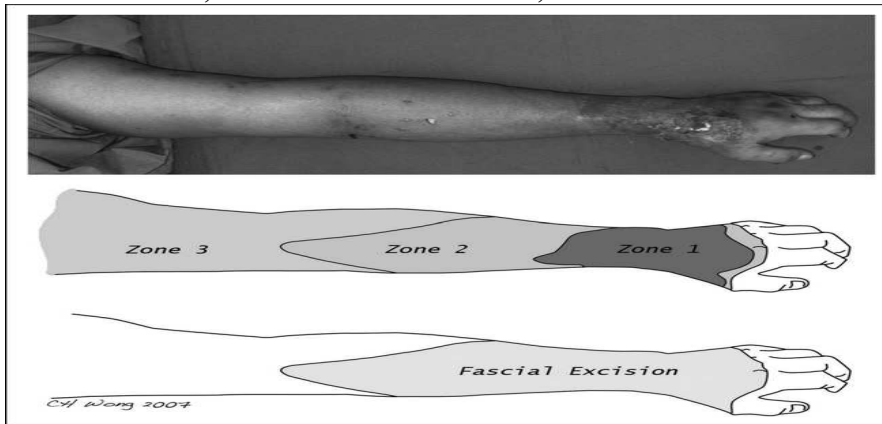


Figure 5: Classification of the involved skin and subcutaneous tissue into zones. Source: Wong *et al.*, (2008).

The infected skin is classified in to 3 zones. Zone 1 (necrotic tissue), Zone 2 (infected but potentially salvageable soft tissue) and zone 3 (non-infected and viable skin). Zone 1 is

completely excisable. Zone 2 is carefully assessable to excise the non-viable tissue while protecting the salvageable tissue. Zone 3 is unaffected; it is therefore left untouched.



Figure 6: Foul-smelling, turbid “dishwater” pus seen in necrotizing fasciitis. Source: Wong *et al.*, (2008).

Figure six above shows approach to debridement in necrotizing fasciitis and exploration of the wound to get access to the dishwater as shown by arrow. This serves as the sample for microscopy, culture and sensitivity test.

Prognosis

Mortality from NF could be up to 75% despite intervention. Delayed surgical intervention for ≥ 24 hours is associated with significant increase in mortality (Cheung *et al.*, 2009). Other reasons of increased mortality are old age, diabetes mellitus and ≥ 2 comorbid illnesses. Patients with NF of the chest, axilla, abdomen, lumber and gluteal regions have the highest mortality while patients with Fournier’s

gangrene have the lowest mortality (Shaikh & Rashid, 2008). Type 2 & 4 necrotizing fasciitis has the worst prognosis among others (Shaikh, *et al.*, 2012).

CONCLUSION

Necrotizing fasciitis is rapidly progressing, inflammatory infection of the fascia with the secondary involvement of skin, subcutaneous tissues and muscle.

It is highly associated with very quick progressive necrosis of any of the layers in the soft tissue compartment, such as dermis, subcutaneous tissue, superficial fascia, deep fascia and muscle. It affects different parts of the body with slight preponderance. It has a high morbidity and mortality. The mortality rate could be up to 100% if not diagnosed and treated early. Thus, it is both medical and surgical emergency. Diagnosis is made using clinical presentation and LRINEC Score. However, microbiological, surgical and histological findings confirm the diagnosis. Immediate resuscitation, early administration of broad-spectrum parenteral antibiotics and early debridement provide a favourable outcome.

RECOMMENDATIONS

The following are recommendable as part of the principle management of necrotizing fasciitis;

1. The use of clinical presentations, parts of the body involved, social history as well as history of comorbid illness in making diagnosis.
2. A Laboratory Risk Indicator for Necrotizing Fasciitis (LRINEC) Score should be assessed to ensure the working diagnosis.
3. Microbiological, surgical and histopathological analysis should be used to confirm the final diagnosis.
4. Immediate medical interventions and administration of broad-spectrum parenteral antibiotics.
5. Early and aggressive debridement is encouraged as soon as possible.
6. Woundcare after debridement and nutritional support should be taken in to consideration in patients with necrotizing fasciitis.
7. Early ambulation is also encouraged to prevent the development of deep veins thrombosis (DVT) and contractures.

REFERENCES

Anaya, D. A., McMahon, K., Nathens, A. B., Sullivan, S. R., Foy H., & Bugler, E. (2005). "Predictors of Mortality and Limb Loss in Necrotizing Soft Tissue Infections," *Archives of Surgery*, 140 (2), 151-157. doi:10.1001/archsurg.140.2.151.

Cheung, J. P., Fung, B., Tang, W. M., & Ip, W. Y. (2009). A review of necrotising fasciitis in the extremities. *Hong Kong Medical Journal*.

Edlich, R.F., (2017). Necrotizing Fasciitis Differential Diagnoses. Available@emedscape.com.

El-Menyar, A., Asim, M., Mudali, I. N., Mekhodathil, A., Latifi, R., & Al-Thani, H. (2017). The laboratory risk indicator for necrotizing fasciitis (LRINEC) scoring: the diagnostic and potential prognostic role. *Scandinavian journal of trauma, resuscitation and emergency medicine*, 25(1), 28.

Frazeo, B. W., Fee, C., Lynn, J., Wang, R., Bostrom, A., Hargis, C., & Moore, P. (2008). Community-acquired necrotizing soft tissue infections: a review of 122 cases presenting to a single emergency department over 12 years. *The Journal of emergency medicine*, 34(2), 139-146.

Goh, T., Goh, L. G., Ang, C. H., & Wong, C. H. (2014). Early diagnosis of necrotizing fasciitis. *British Journal of Surgery*, 101(1).

Hernández, D. A. A., Manuel, A., Chávez, G., & Rivera, A. S. (2017). Facial Necrotizing Fasciitis in Adults. A Systematic Review.

Irwin, K., and English, W., (2013). The Diagnosis and Management of Necrotising Fasciitis Anaesthesia Tutorial of the Week 298.

Legbo, J. N., & Shehu, B. B. (2005). Necrotizing fasciitis: a comparative analysis of 56 cases. *Journal of the National Medical Association*, 97(12), 1692.

Misiakos, E. P., Bagias, G., Patapis, P., Sotiropoulos, D., Kanavidis, P., & Machairas, A. (2014). Current concepts in the management of necrotizing fasciitis. *Frontiers in surgery*, 1.

Miller, L. G., Perdreau-Remington, F., Rieg, G., Mehdi, S., Perlroth, J., Bayer, A. S., & Spellberg, B. (2005). Necrotizing fasciitis caused by community-associated methicillin-resistant *Staphylococcus aureus* in Los Angeles. *New England Journal of Medicine*, 352(14), 1445-1453.

Morgan, M.S., (2010). Diagnosis and Management of Necrotizing Fasciitis *Journal of Hospital Infection*, 75(4), 249-257. doi:10.1016/j.jhin.2010.01.028

- Mulcahy, H., & Richardson, M. L. (2010). Imaging of necrotizing fasciitis: self-assessment module. *American Journal of Roentgenology*, 195(6_supplement), S66-S69.
- Nagano, N., Isomine, S., Kato, H., Sasaki, Y., Takahashi, M., Sakaida, K., & Arakawa, Y. (2008). Human fulminant gas gangrene caused by *Clostridium chauvoei*. *Journal of clinical microbiology*, 46(4), 1545-1547.
- Ndukwe, K.C., Fatusi, O.A., & Ugboko, VI. (2002). Craniocervical Necrotizing fasciitis in Ile Ife, Nigeria. *Br J Oral Maxillofac Surg*, (40), 64-7.
- Obiechina, A.E., Arotiba J.T., & Fasola A.O. (2001). Necrotizing fasciitis of odontogenic Origin in Ibadan Nigeria. *Br J Oral Maxillofac Surg*, (39), 122-6.
- Obimakinde, O. S., Okoje, V. N., Akinmoladun, V. I., Fasola, A. O., & Arotiba, J. T. (2012). Retrospective evaluation of necrotizing fasciitis in university college hospital, Ibadan. *Nigerian journal of clinical practice*, 15(3), 344-348.
- Ozturk, S., Zor, F., Karlioglu, Y., & Sengezer, M. (2005). Idiopathic neonatal necrotizing fasciitis of the scalp: a case report. *European Journal of Plastic Surgery*, 28(5), 368-370.
- Roje, Z., Roje, Z., Matic, D., Librenjak, D., Dokuzovic, S., Varvodic, J., (2011). Necrotizing fasciitis: literature review of contemporary strategies for diagnosing and management with three case reports: torso, abdominal wall, upper and lower limbs. *World J Emerg Surg*, 23(6) 46.
- Ruiz-Tovar, J., Córdoba L., & Devesa J.M., (2012). Prognostic factors in Fournier gangrene. *Asian J Surg*, 35, 7-41
- Sarani, B., Strong, M., Pascual, J., & Schwab, C. W. (2009). Necrotizing fasciitis: current concepts and review of the literature. *Journal of the American College of Surgeons*, 208(2), 279-288.
- Seal, D. V. (2001). Necrotizing fasciitis. *Current opinion in infectious diseases*, 14(2), 127-132.
- Shaikh, N. (2006). Necrotizing Fasciitis, a Decade of Surgical Intensive Care Experience, *Indian Journal of Critical Care Medicine*, 10(4) 225-229.
- Shaikh, N., Khawaiter, J., & Al-Thani, H. (2012). Necrotizing fasciitis: a surgical and medical emergency. *Surgical Science*, 3(11), 518.
- Shaikh, N., & Rashid, A., (2008,). "Regional Necrotizing Fasciitis and Its Outcome," *Qatar Medical Journal*, 17(1) 24-27.
- Shimizu, T., & Tokuda, Y. (2010). Necrotizing fasciitis. *Internal Medicine*, 49(12), 1051-1057.
- Wang, Y., Wong, C., and Tay, Y. (2007). Staging of necrotising fasciitis based on the evolving cutaneous features. *Int J Dermatol*, 46(1036) 1041.
- Wilson B., (1952). "Necrotizing Fasciitis," *The American Journal of Surgery*, 18(4), 416-431.
- Wong, CH., Khin, LW., Heng, KS., Tan, KC., Low, CO (2004). The LRINEC (laboratory risk indicator for necrotizing fasciitis) score: a tool for distinguishing necrotizing fasciitis from other soft tissue infections. *Crit Care Med*, 32(1535) 41.
- Wong, C. H., Yam, A. K. T., Tan, A. B. H., & Song, C. (2008). Approach to debridement in necrotizing fasciitis. *The American Journal of Surgery*, 196(3), e19-e24.
- Yadav, S., Verma, A., Sachdeva, A., (2012). Facial necrotizing fasciitis from an odontogenic infection. *Oral Surg Oral Med Oral Pathol Oral Radiol*, 113: 1-4.